



Offloading only as a means of management of neuropathic ulcers: A Case series

Dr. Aradhana Shukla¹, Dr. Mahesh Choudhary², Dr. Anil Kumar Gaur³

¹ PG Student, III year, Department of All India Institute of Physical Medicine and Rehabilitation, Keshavrao Khadye marg, Hajiali Mumbai- 400034)

² MS., ORTHOPAEDICS, Specialist PMR, Department of All India Institute of Physical Medicine and Rehabilitation, Keshavrao Khadye Marg, Hajiali Mumbai- 400034)

³ DNB, PMR, Director and Consultant, All India Institute of Physical Medicine and Rehabilitation, Keshavrao Khadye Marg, Hajiali Mumbai- 400034

ABSTRACT:

Neuropathic ulcers have been a cause of ongoing disability in vast majority of patients affected with conditions causing sensory impairment in the extremities, especially the lower extremities. Repeated weight bearing on the insensate and deformed part leads to skin breakdown, subsequent infection and chronic ulceration. Bony changes in the form of Charcot's arthropathy are also evident in many cases. Sometimes such patients land into amputations as a consequence. Neuropathic ulcers can be due to various etiologies like diabetes, leprosy, spinal dysraphism or acquired spinal cord insults.

Various techniques of management of Neuropathic ulcers are described in literature ranging from debridement, Total contact casting, various dressing materials, antibiotics and orthotic modifications.

We describe a case series of 4 cases where thorough debridement and offloading only was used for management of these ulcers with excellent results.

Keywords: Neuropathic, Weight bearing, Charcot.

INTRODUCTION:

Neuropathic ulcers result from repetitive trauma to hyposensate distal extremities (e.g., feet and, not uncommonly, tips of the fingers), usually on weight-bearing bony prominences such as metatarsal heads. In the case of uncomplicated neuropathic ulcers, the circulation is usually functionally intact [1]. Neuropathic ulcers require immediate attention in terms of relief of abnormal repetitive pressure and shear stress, along with specific formulation of treatment strategies of the etiologies with underlying neuropathy [1].

As seen neuropathic ulcers are seen in patients with diabetes, leprosy, spinal dysraphism, congenital sensory neuropathy, etc. The most common cause of neuropathic ulcers is diabetes in which the mechanism described as insensitivity, microangiopathy, and altered inflammatory response, foot deformities (intrinsic minus, Charcot), blunted reactive hyperemia, reduced incision breaking strength, and contraction, whereas in pediatric population the most common cause of neuropathic ulcers are spinal dysraphism in which because of sensory and motor imbalance, movement is restricted, potentially inciting tissue ischemia leading to pressure necrosis and foot

abnormalities may create pressure points, which may further lead to pressure necrosis[1]. Children have shown to have higher risk of skin pressure breakdown due to increased pressure of a larger body habitus and asymmetric weight bearing [4].

We report four cases of neuropathic ulcers managed by thorough debridement and offloading with excellent healing.

Material and methods:

Case 1.

11-year-old boy, operated case of menigomyelocele, with impaired sensations from L1 level to L3 and absent sensation from L4 onwards S4-S5. He presented non-healing ulcer of left heel of duration 2 years. The ulcer presented with serous discharge, fibrosed margins, pale edges and floor covered with slough. He was regularly subjected to dressing on an OPD basis, but not offloading. Ulcer never healed.

Management- when reported, culture and sensitivity was done of wound floor and imaging were done [5]. No active involvement of calcaneum foot was there but margins seemed mildly sclerosed. He was put on susceptible antibiotics 2 days prior to surgery. Extensive surgical debridement was done, and sutures were taken. Patient was given below knee casting and through window dressing was done with normal saline only every 5 days along with strict offloading.

Ulcers completely healed by 6 weeks and sutures were removed the same time. The patient was maintained on antibiotics for complete 6 weeks and Vitamin C and zinc supplements.

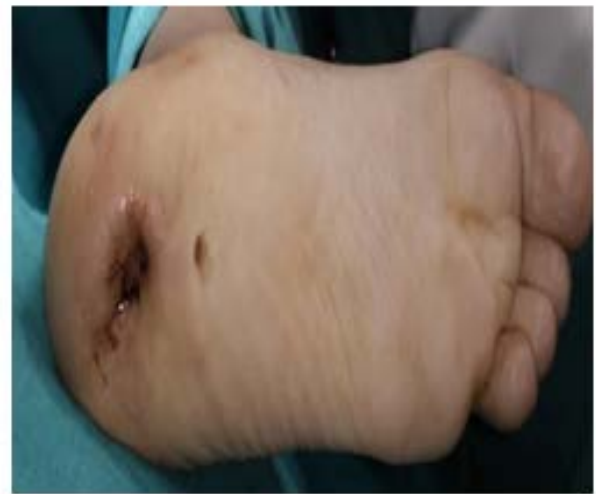

Fig. 1. Pre-operative

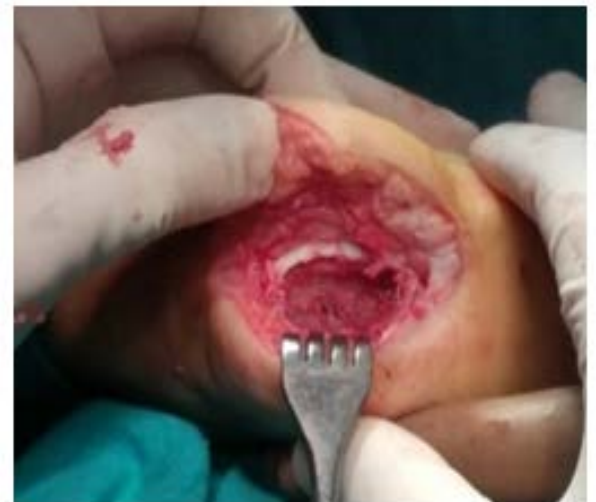

Fig. 2. Intra-operative

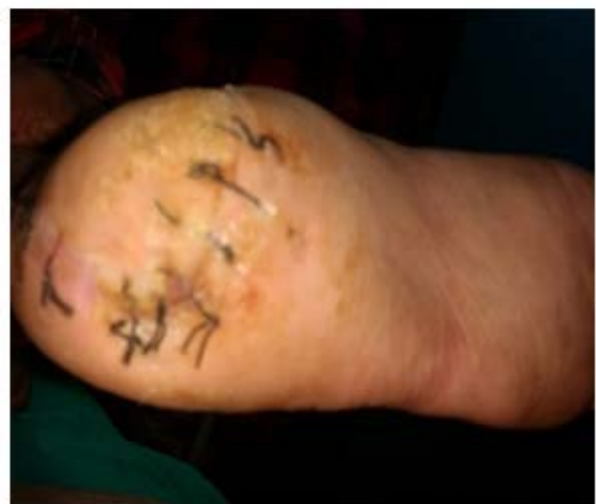

Fig. 3. Post-operative. Healed ulcer. Sutures in situ.

Case 2.

15-year-old female, operated case of meningomyelocele with impaired sensation from T12-L3 and absent sensation from L4 to S5. She presented with a non-healing ulcer of left heel of duration 3 years. Compliance to regular dressing was poor and the wound worsened in last 1 year. The ulcer was 1.5 cm x 1.5 cm x 2 cm in dimensions, had calloused margins, fibrosed edges and pale tissue covered floor. The base was calcaneum. There was serous discharge present, not foul smelling.

Management- preliminary investigations including culture and sensitivity and imaging were done. Appropriate antibiotics were started before taking patient for surgical debridement and any signs of osteomyelitis were ruled out. After surgical debridement as the edges were non-opposing the wound was covered with sterile gauge piece and then secured in a below knee casting. After one-week dressing through window was started with normal saline only every 5-6 days. Strict offloading during the period was ensured. For ambulation she was allowed the use of wheelchair.

After 8 weeks complete healing of ulcer was achieved which was further taken care by appropriate orthosis prescription. She was given antibiotics course for the entire healing period. Patient is still in follow-up.

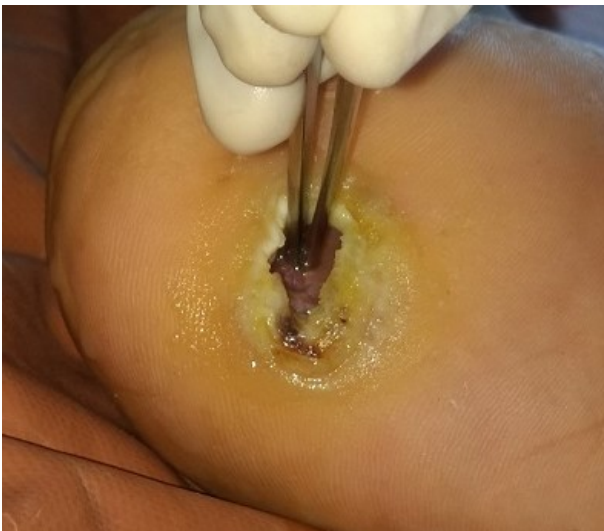

Fig. 1. Pre-operative

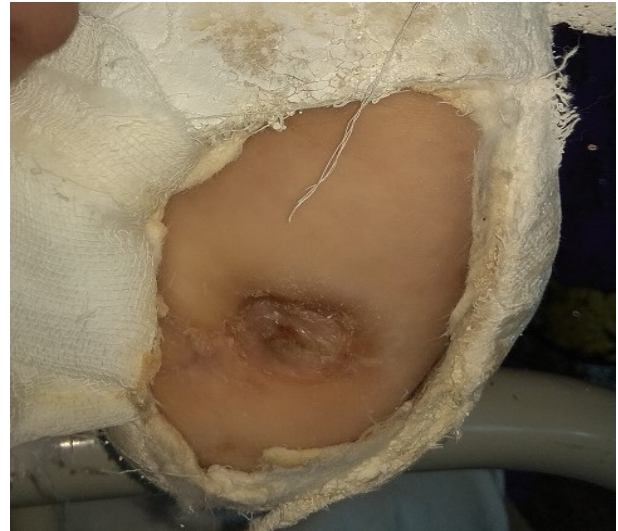

Fig. 2. Post-operative. Dressing through window in POP cast.

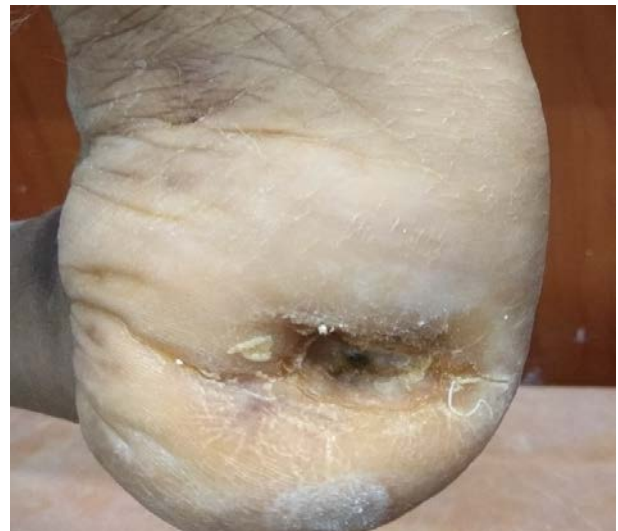

Fig. 3. Post-operative healed ulcer by scarring.

Case 3;

21-year-old operated case of meningomyelocele, reported with a non-healing ulcer of left heel of duration 2 years. The ulcer presented with serous discharge and dimensions were 3cm x 3 cm x 4 cm. The patient did not respond to regular dressing. The ulcer has calloused heaped up margins with pale edges and slough at floor. Base was calcaneum and about 2-3 mm bone was visible on the floor. There was no pus discharge, no h/o fever, limb swelling or limb discoloration.

Management- baseline blood parameters with imaging and culture sensitivity was done.

Susceptible antibiotics were started and after 2 days surgical debridement was done and as the margins were non-opposing the wound was covered with sterile normal saline soaked gauge and below knee casting done. Further management remained the same with regular dressing through window using normal saline and continuation of antibiotics. Healthy scar tissue was seen within a period of 5 weeks. Stringent offloading regime was followed. For ambulation axillary crutches were used.

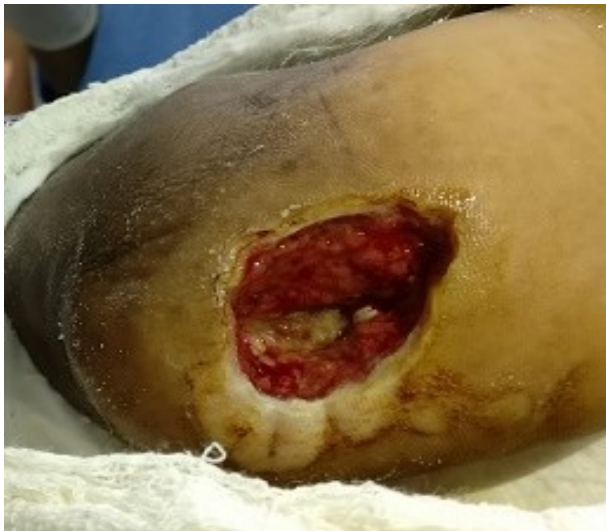

Fig. 1. 5 days post-surgical debridement.

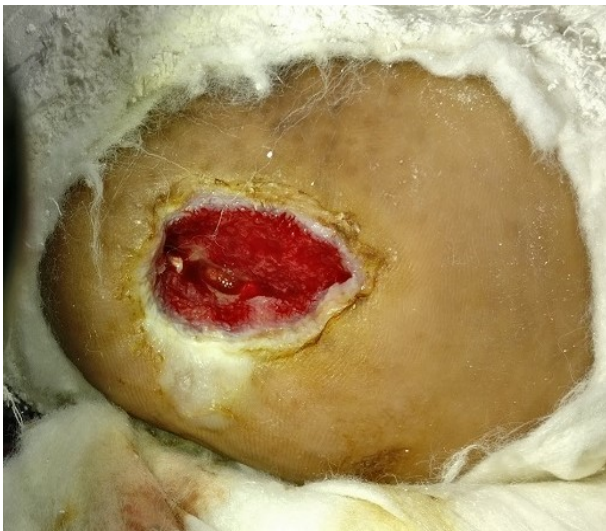

Fig. 2. Post-operative 2nd dressing through window

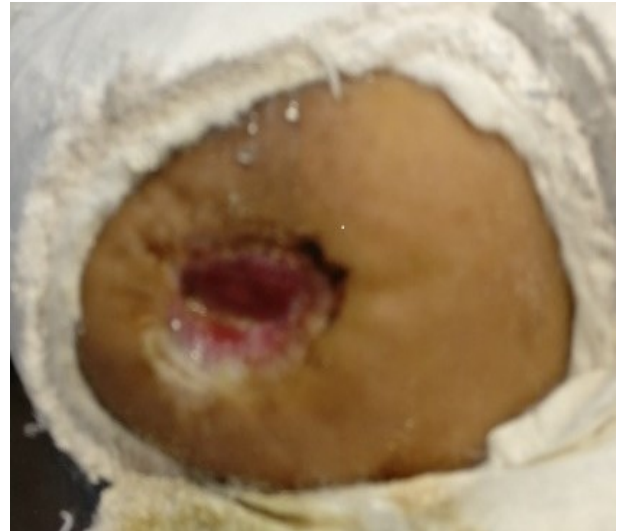


Fig. 3. Post-operative 3rd dressing

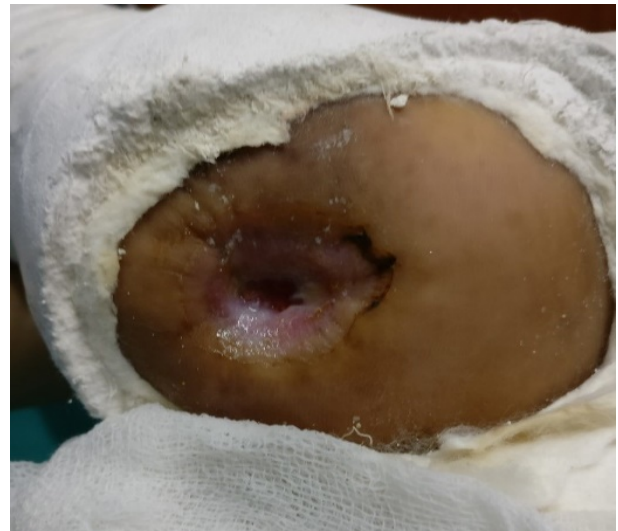

Fig. 4. Post-operative week 3.

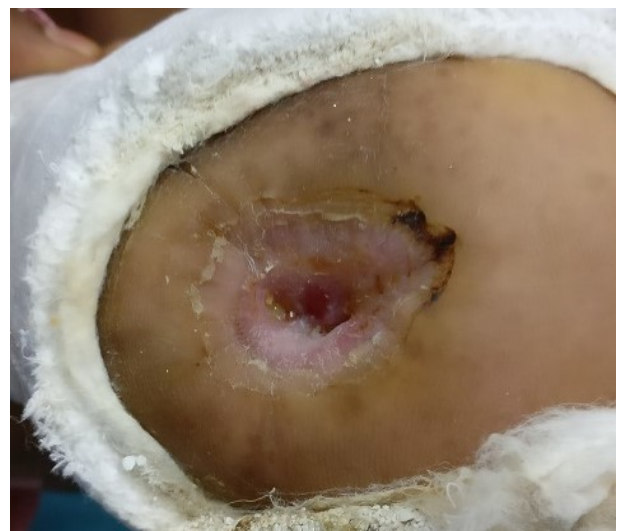

Fig. 5. Post-operative week 4

Case 4;

44-year-old male, a case of traumatic spinal cord injury level D11 with absent sensation from L3-S5 reported with a chronic non-healing ulcer of left Heel which was foul smelling and had maggots, dimensions of ulcer were 2cm x 2cm x 4 cm with dirty looking heaped-up calloused margins with edges not clearly visible and slough covering the floor which rested upon calcaneum. Patient had some discoloration over left ankle foot s/o chronicity of the condition but there was no subcutaneous crepitations or diminished pulses.

Management- after investigations initially the patient was given a regular dressing to clear active local infection with starting of appropriate antibiotics. As soon as he was cleared of local infection and maggots, surgical debridement was carried out and he was maintained with an open wound in a cast which was regularly cleaned and dressed with normal saline. His nutrition and micronutrient supplementation were also taken care of. Focus was to achieve healthy fibrous scar tissue on which partial weight bearing could be achieved. He achieved complete healing within a period of 2 months. Now he has been provided with moulded insole in footwear and is under regular follow up.

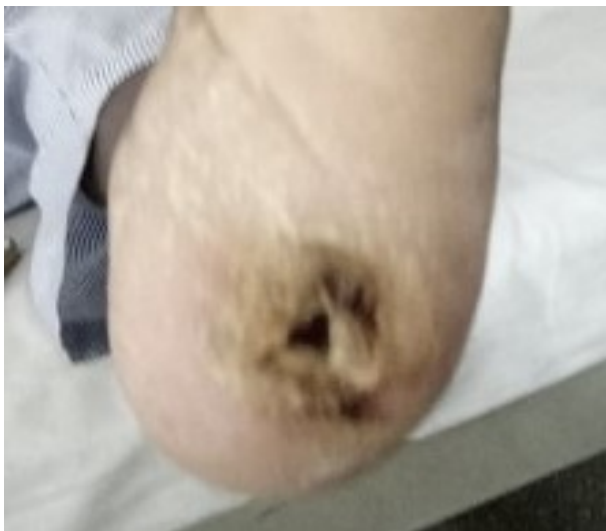

Fig. 1. Pre-operative

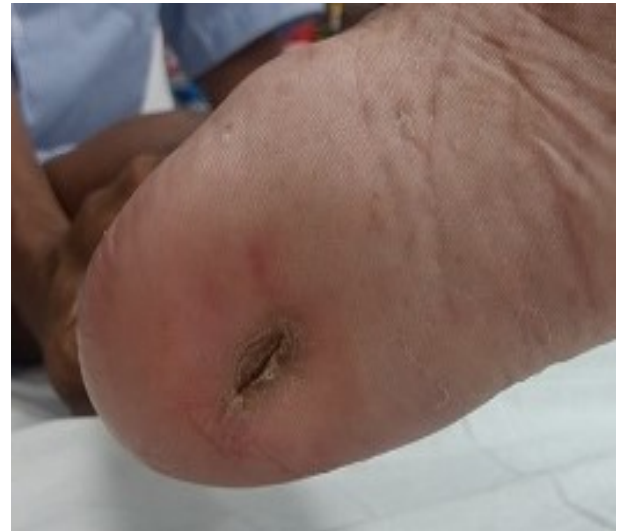

Fig. 2. Post-operative. Healed scar.

Discussion

Neuropathic foot ulceration is common in patients who have low lumbar or sacral involvement. Patients may have paraparesis or paraplegia and may be incontinence of bladder and bowel [2]. On examination demonstration of loss of sensation as light touch, pin prick, hot and cold can be done as well varying degree of motor loss in lower limb as result of same [8]. Examination can reveal the level and extent of weakness in such patients.

Clinically ulcers vary in their appearances and presentation in every patient, but pathogenesis stays the same. Patient's current general condition, nutritional status and local circulation plays an important role in the wound clinical presentation. The physical examination of an uncomplicated foot ulcer typically shows peripheral pulses to be intact, but sensation is diminished or absent near the ulcer. Ulcers are most frequently located on bony prominences of the plantar metatarsals, midfoot, or heel. Ulcers usually have regular borders and exuberant surrounding callus formation [1]. These ulcers occur rapidly but are usually slow to heal. Physical examination of ulcer should be accurate in view of its reproducibility once management starts. Culturing the ulcer may be helpful to determine the presence of local infection [2]. Total leucocyte count, differential leucocyte

count, and C-reactive protein (CRP) ascertain the presence of systemic infection. Radiographs of the involved areas are used to check for osteomyelitis; an abnormal radiograph, bone scan, or CRP level also may help distinguish an infected ulcer requiring long-term antibiotic therapy from a chronic ulcer that might benefit from consultation with a wound care specialist.

Treatment includes nutrition considerations [7], edema management, offloading and management of gait and foot deformity, medication management (including topical treatment), surgical options, adjunctive therapies, patient education, and health care provider follow-up. Other protocols of care regarding wound assessment and management do not differ in this population [6]. Although these treatment protocols have been talked about and written and published [9], there is not much in literature in specific to the treatment protocol for the neuropathic ulcer in spinal dysraphism per se. For pressure ulcer various dressings for wound healing are mentioned in literature but not specific that fits to our patient profile. Also, the orthotics and footwear modification have been greatly talked about diabetic foot ulcer management [3], but these poses certain amount of difficulty issues in compliance in ulcer management of pediatric population.

In our patients with neuropathic ulcer management we stuck to the basics of wound debridement, infection control and a very strict offloading regimen until the wound is healed to a stage where weight bearing can be started with proper precautions. We made sure not to use any cytotoxic agents not even in vicinity of wounds after surgical debridement, maintaining most environment by use of normal saline. Except one, none of the wounds after thorough surgical debridement were closed by suturing, they were maintained in a POP cast and wound check and dressing were performed every 3-5 days depending upon the assessment of wound. The POP application was also helpful in ensuring

stringent offloading regimen up to complete healing of the wound. Before the surgical debridement the patients were started off with an empirical antibiotic two days prior and in the operating room, the wound tissue samples retrieved under proper aseptic precautions were send for culture and sensitivity. As the sensitivity reports arrived we made sure of the administration of the susceptible antibiotic to the patient for a minimum of 6 weeks. Considering the nutrition of patients, they were provided protein 1.5 gm/kg/day, vitamin C 1000mg/day and zinc 104 mg/day as supplement apart from there regular diet. No other interventions were done.

Conclusions

As described, avoidance of prolonged pressure, care of bony prominences, and maintenance of foot flexibility are important for prevention of ulcer formation. But once the ulcer develops, treatment of both the ulcer and neuropathy if possible is required. Even there are many new dressings, orthotic management and various alternate ways of treatment of these ulcers are described, the best way and the crux of treatment remains the same, i.e. offloading. When prescribed and followed diligently it proved to be the single most effective factor in treating chronic neuropathic ulcers even though after surgery as required in most recalcitrant cases and can prevent unfortunate risks of amputations [11]. Treatment of foot ulcers which might need a bony procedure always comes with an amount of significant risk [10]. Unfortunately, few studies on the prevention and management of trophic ulcers in pediatric patients with NTD have been conducted, limiting clinicians' ability to make evidence-based decisions [2].

References

1. Goldman, R, de Leon J, Popescu A, Salcido R. Braddoms physical medicine and rehabilitation. 5th ed. Elsevier; 2016.
2. Neuropathic Ulcers Among Children with Neural Tube Defects: A Review of Literature.

- Anand Pandey, Vipin Gupta, Shailendra P. Singh, Vijendra Kumar, Rajesh Verma. *Ostomy Wound Manage.* 2015 Dec; 61(12): 32–38.
3. Off-loading total contact cast in combination with hydrogel and foam dressing for management of diabetic plantar ulcer of the foot. Tanawat Vaseenon, Songwut Thitiboonsuwan, Chaiyarit Cheewawattana-chai, Punngam Pimchoo, Areerak Phanphaisarn. *J Med Assoc Thai.* 2014 Dec; 97(12): 1319–1324.
 4. Thomson HG, Azhar Ali M, Healy H. The recurrent neurotrophic buttock ulcer in the meningomyelocele paraplegic: a sensate flap solution. *Plast Reconstr Surg.* 2001;108(5):1192–1196.
 5. Houston DS, Curran J. Charcot foot. *Orthop Nurs.* 2001;20(1):11–15.
 6. Schultz GS, Sibbald RG, Falanga V, Ayello EA, Dowsett C, Harding K, et al. Wound bed preparation: a systematic approach to wound management. *Wound Repair Regen.* 2003;11(suppl 1):S1–S28.
 7. Rodriguez-Key M, Alonzi A. Nutrition, skin integrity, and pressure ulcer healing in chronically ill children: an overview. *Ostomy Wound Manage.* 2007;53(6):56–62.
 8. Okamoto GA, Lamers JV, Shurtleff DB. Skin breakdown in patients with myelomeningocele. *Arch Phys Med Rehabil.* 1983;64(1):20–23.
 9. Edwards J, Stapley S. Debridement of diabetic foot ulcers. *Cochrane Database Syst Rev.* 2010;20(1):CD003556.
 10. Maynard MJ, Weiner LS, Burke SW. Neuropathic foot ulceration in patients with myelodysplasia. *J Pediatr Orthop.* 1992;12(6):786–788
 11. Srivastava VK. Wound healing in trophic ulcers in spina bifida patients. *J Neurosurg.* 1995;82(1):40–43.

ACKNOWLEDGEMENTS: Faculty and staff
(Department of PMR, AIIPMR, MUMBAI)

CONFLICTS OF INTEREST: NONE