



STUDY BETWEEN SURGICAL FIXATION OF PATELLA WITH CERCLAGE AND TENSION BAND WIRING TECHNIQUE AT SSPM'S MEDICAL COLLEGE

Dr. Shashikant Ramrao Bhange

Associate Professor Mimer Medical College Talegaon

Conflicts of Interest: Nil

Corresponding author: Dr. Shashikant Ramrao Bhange

Abstract:

Introduction: In human body among the skeletal system patella is the largest sesamoid bone in the quadriceps tendon in the body. The main function of patella is to improve the efficiency of quadriceps muscle by improving the mechanical leverage of the quadriceps muscle. Usually with direct trauma there is occurring of patellar fracture. Surgery is required for about one third of patella fracture that indicated damage to the extensor mechanism. In a country like India any improper and inadequate treatment would inevitably lead to a great deal of disability where scooching is an important activity in daily life. Regarding treatment of patellar fracture there is a controversy since earliest time. In the fracture of patellar with displacement less than 3mm, conservative treatment was suggested as the best option. There are various methods used for ORIF of these fractures tension band wiring (TBW) technique using wires and most commonly used is stainless steel wires. In the treatment of TBW which works by converting tensile forces into compressive forces when movements occur at the knee joint. However TBW is consider as current gold standard for the displaced transverse patella fractures whereas some surgeons recommend augmentation of TBW with circumferential cerclage wiring to enhance the strength of the fixation.

Aim: The main aim was study between fracture fixation of patella with cerclage and Tension Band wiring technique.

Material and methods: Total 62 patients with fracture of patella were included in this study with the age more than 20 years. Among total patients were divided into two groups as group I (n=30) include fracture treated with tension band wiring (TBW) along with augmented circumferential cerclage wiring whereas in group II (n=32) included fractures treated by TBW along. Patients with fracture of patella, extensor mechanism lag at knee and with closed injury were included in this study. Almost for all the patients surgery was performed and tourniquet was also used. By using a midline longitudinal incision surgery was done over anterior aspect of the knee. By using tension band wiring with or without augmented cerclage with stainless steel wire open reduction and internal fixation were done. After the surgery as post operative knee brace was given so that patients could start range of motion at knee without pain. To make sure that whether proper fixation was done or not Post-operative radiographs were also done.

Result: In this study total 50 patients were included in which 34(68%) were male and 16(32%) were female. Among 50 patients was included different age group in which more patients were in the age group of 40-50 years old as 36%.

Conclusion: Conservative treatment is only in un-displaced fractures. For the fracture of patella it is important for operative treatment to carry out repair of torn expansion of quadriceps and gives good results. Therefore, in the fracture of patella modified TBW was better than encirclage wiring in treatment probably because of good stability of implant and easier postoperative rehabilitation. Hence use of circumferential cerclage wiring along with tension band wiring for fractures of patella has no added advantage over fixation with tension band wiring alone.

Keywords: Patella fracture, Cerclage wiring, Tension band wiring

Introduction

In human body among the skeletal system patella is the largest sesamoid bone in the quadriceps tendon in the body. The main function of patella is to improve the efficiency of quadriceps muscle by improving the mechanical leverage of the quadriceps muscleⁱ. In the human body, fracture occurring in all skeletal fracture about 1% occur as patella fractureⁱⁱ. Usually with direct trauma there is occurring of patellar fracture. Surgery is required for about one third of patella fracture that indicated damage to the extensor mechanismⁱⁱⁱ. Due to the violent contraction of the quadriceps results in

indirect fractures of the patella. Fractures are usually transverse and are associated with tears of medial or lateral retinaculum. In a country like India any improper and inadequate treatment would inevitably lead to a great deal of disability where scooching is an important activity in daily life. Regarding treatment of patellar fracture there is a controversy since earliest time. In the fracture of patellar with displacement less than 3mm, conservative treatment was suggested as the best option^{iv, v}. Due to small bone fragments comminution extra articular fracture of the distal pole of patella are difficult which reduce and

maintain reduction due to the extension mechanism of the knee^{vi, vii, viii & ix}.

Common procedure to attach patellar tendon to the patella by transosseous pull out suture after removal of bone fragments^x. In the fracture of patella most of the fracture are displaced and associated with failure of extensor mechanism at knee. Such kind of cases treatment as open reduction and internal fixation (ORIF) is the recommended which restore the extensor mechanism and augment fracture healing to ascertain early knee movements^{xi, xii}. There are various methods used for ORIF of these fractures tension band wiring (TBW) technique using wires and most commonly used is stainless steel wires^{xiii, xiv}. In the treatment of TBW which works by converting tensile forces into compressive forces when movements occur at the knee Joint. However TBW is consider as current gold standard for the displaced transverse patella fractures whereas some surgeons recommend augmentation of TBW with circumferential cerclage wiring to enhance the strength of the fixation^{xv, xvi, xvii & xviii}. The main aim was study between fracture fixation of patella with cerclage and Tension Band Wiring technique.

MATERIAL AND METHODS:

This study was carried out in the Department of Orthopedics in collaboration with Dept. of Surgery at SSPM’S Medical College Sindhudurg and hospital, during the period of 1 year. Total 62 patients with fracture of patella were included in this study with the age more than 20 years. Among total patients were divided into two groups as group I (n=30) include facture treated with tension band wiring (TBW) along with augmented circumferential cerclage wiring whereas in group II (n=32) included fractures treated by TBW along. From all the patients for the records of data as documentation was collect by physical examination, past and present history and medical assistance and investigation such as Mode of Injury, surgery, radiographies, type of fracture and pattern of fracture were taken.

Patients with facture of patella, extensor mechanism lag at knee and with closed injury were included in this study. Almost for all the patients surgery was performed and tourniquet was also used. By using a midline longitudinal incision surgery was done over anterior aspect of the knee. By using tension band wiring with or without augmented cerclage with stainless steel wire open reduction and internal fixation were done. Using

two K wires and stainless-steel wire Tension band wiring was also done. After the surgery as post operative knee brace was given so that patients could start range of motion at knee without pain. To make sure that whether proper fixation was done or not Post-operative radiographs were also done.

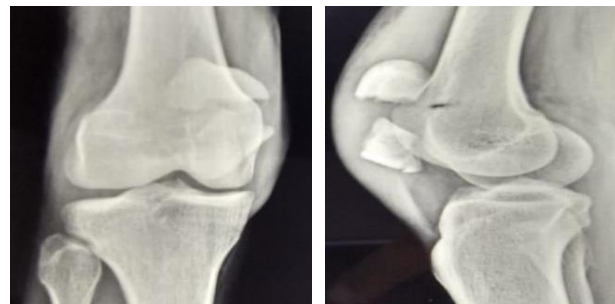

Figure 1: (A) Pre-operative radiograph (AP view). (B) Pre-operative radiograph (lateral view).

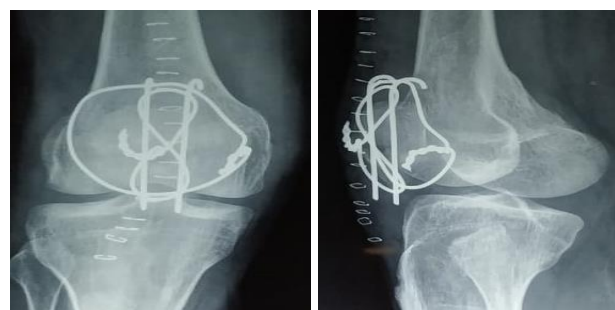

Figure 2: (A) Post-operative radiograph in (B) Post-operative radiograph in group 1 (AP view). group 1 (lateral view).

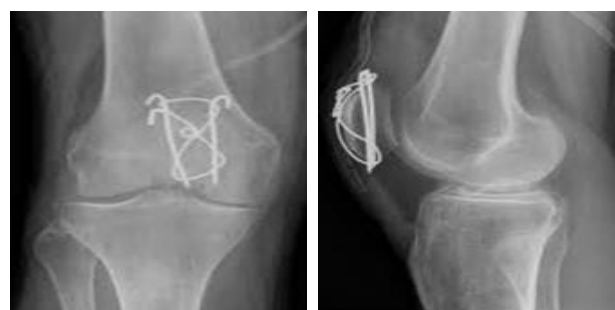


Figure 3: (A) Post- operative radiograph (B) Post-operative radiograph in in group 2 (AP view). group 2 (lateral view).

For every patients followed up were also done every 2 weeks for first two months and after that once in a month. At the time of followed up each patients were examined for both subjective symptoms and objective signs which were noted. Mobilization of the knee was started at the fourth week in TBW patients, whereas the sixth week in encirclage patients.

Table 1: Showing scoring of outcome.

Score	4	3	2	1
knee pain	No pain	Mild	Moderate	Severe
Knee stiffness	No Stiffness	Mild	Moderate	Severe
Quadriceps wasting	0-1.5 cm	1.6-2.5 cm	2.6-3.5cm	>3.5 cm
Knee extension loss	0°- 5°	6°- 10°	11°- 20°	>20°
Knee flexion loss	0°- 10°	11°- 20°	21°- 30°	>30°

Table 2: Showing grading of outcome.

Result	Overall score
Excellent	16-20
Good	12-15
Fair	08-11
Poor	04-07

The patients were followed every monthly for 6 months post-operatively. Outcome was studied, graded and compared on the basis of knee pain, knee stiffness, quadriceps wasting, loss of flexion and loss of extension as shown in table no 1 and 2.

Result:

In this study total 50 patients were included in which 34(68%) were male and 16(32%) were female as shown in table no 1 below.

Table 3: Showing gender wise distribution

Gender	no.	%
male	34	68
female	16	32
total	50	100

Among 50 patients with different age group were included. In this study, more than 19 years to 80 years old patients were included as shown in table no 2 below. In this study more patients were in the age group of 40-50 years old as 36%.

Table 4: Showing age wise distribution (in years).

Age wise distribution	no	%
20-30	5	10
30-40	12	24
40-50	18	36
50-60	9	18
more than 60	6	12
total	50	100

In this study group I showed excellent in 3 patients (14.3%), good in 12 patients (57.1%), fair in 5 patients(23.8%) and poor in 1 patient(4.8%) and in

group II showed excellent in 4 patients (13.8%), good in 16 patients (55.2%), fair in 7 patients(24.1%) and poor in 2 patient(6.9%) as shown in the table below. In this study patients also has to suffer from few complications post operatively including infection, fixation failure and nonunion among both the groups. In these cases infections were managed with daily debridement and dressings were done along with proper antibiotics. Fixation failure and nonunion were managed with revision surgery with bone grafting. After revision surgery union was achieved in all the cases of fixation failure and nonunion.

Table 5: Showing results based on clinical grading of outcome.

Result	Group I		Group II	
	Patients	%	Patients	%
Excellent	3	14.3	4	13.8
Good	12	57.1	16	55.2
Fair	5	23.8	7	24.1
Poor	1	4.8	2	6.9
Total	21	100	29	100

DISCUSSION:

In the body facture of the patella are managed with tension band wiring (TBW) which is considered as the gold standard. Some researchers showed that when circumferential cerclage wiring added to the TBW has been regarded to improve the strength of the construct^{xix, xx, xxi}. In the studied of Curtis et al showed that addition of cerclage wiring to the TBW significantly adds to the strength of the construct^{xxii}. In this study total 50 cases were included with facture of patella in which all the facture were closed injuries. In this study total 50 patients were included with the age range from 20 – 80 years old. Most of the patients were aged more than 40 years. Among 50 patients 34(68%) were male and 16(32%) were female. Total patients were divided into 2 groups as group I (n=21) included patients which were managed with TBW along with circumferential cerclage wiring whereas in group II (n=29) included patients which were managed with TBW alone. All the patients were advice for the followup and followed every monthly for a period of 6 months. At the time of followup clinical outcome were recorded with grading to compare the results in the two groups. Among 21 patients in group I showed 71.43% and in group II showed 68.97% excellent to good results. Fixation failure and necessary for

revision surgery among group I and group II was found to be 8.2% and 9.5% respectively. In some patients infections and nonunion also occurred which were managed with daily debridement and antiseptic dressings along with proper antibiotics whereas Fixation failure and nonunion were managed with revision surgery with bone grafting. After revision surgery union was achieved in all the cases of fixation failure and nonunion. According to studied of Srinivaslu et al^{xxiii} union was seen in all cases at 8-12 weeks in

TBW and 10-14 weeks in Encirclage group as compared to this study. In the series of Rudolph and Rosenberg showed 84% of cases excellent to good results and remaining showed poor results^{xxiv}.

CONCLUSION:

Patella is important for effective function of quadriceps and proper biomechanics of knee joint. Thus, it should be preserved wherever possible. Conservative treatment is only in undisplaced fractures. For the fracture of patella it is important for operative treatment to carry out repair of torn expansion of quadriceps and gives good results. Therefore, in the fracture of patella modified TBW was better than encirclage wiring in treatment probably because of good stability of implant and easier postoperative rehabilitation. Hence use of circumferential cerclage wiring along with tension band wiring for fractures of patella has no added advantage over fixation with tension band wiring alone.

REFERENCES:

1. Jabshetty AB. A comparative study of modified tension band wiring and cerclage wiring. *Indian J Sci Tech.* 2011;4(10):25-9.
2. Lotke PA, Ecker ML. Transverse fractures of the patella. *Clin Orthop.* 1981; 158: 180-4
3. Carpenter JE, Kasman R, Matthews LS. Fracture of the patella: *Instr Course Lect.* 1994; 43: 97-108.
4. Marya SK, Bhan S, Dave PK. Comparative study of knee function after patellectomy and osteosynthesis with a tension band wiring following the patellar fracture. *Int Surg.* 1987;72(4).290-3.
5. Walter BM, Axel KK, Stephen. Indications and results of non-operative treatment of patellar fractures. *Clinical Ortho Rel Res.* 1993;289:197-201.
6. Bostrom A. Fracture of the patella. A study of 422 patellar fractures. *Acta Orthop Scand Suppl.* 1972;143:1-80.
7. Johnson EE. Fractures of the patella. In: Rockwood CA, Green DP, eds. *Fractures in adults.* Vol. 2. 4th

- ed. Philadelphia: Lippincott Williams & Wilkins; 1996. p1956-72.
8. Yang KH, Byun YS. Separate vertical wiring for the fixation of comminuted fractures of the inferior pole of the patella. *J Bone Joint Surg Br.* 2003;85:1155-60.
9. Kim ID, Ihn JC, Kim PT, Park BC, Lyu YG, Park IH, Bae CP. A clinical study of the patellar fracture. *J Korean Knee Soc.* 1991;3:157-63.
10. Labitzke R. From "bone suture" to modern osteosynthesis—a chronology. *Chirurg.* 1995;66:452-8.
11. Yamaguchi GT, Zajac FE. A planar model of the knee joint to characterize the knee extensor mechanism. *J Biomechan.* 1989;22(1):1-0.
12. Grelsamer RP, Weinstein CH. Applied biomechanics of the patella. *Clinic Orthopaed Related Res.* 2001;389:9-14.
13. Hung LK, Chan KM, Chow YN, Leung PC. Fractured patella: operative treatment using the tension band principle. *Injury.* 1985;16(5):343-7.
14. Chalidis BE, Sachinis NC, Samoladas EP, Dimitriou CG, Pournaras JD. Is tension band wiring technique the "gold standard" for the treatment of olecranon fractures? A long-term functional outcome study. *J Orthop Surg Res.* 2008;3.
15. Stoffel K, Klaue K, Perren SM. Functional load of plates in fracture fixation in vivo and its correlate in bone healing. *Injury.* 2000;31:37-86.
16. Baran O, Manisali M, Cecen B. Anatomical and biomechanical evaluation of the tension band technique in patellar fractures. *Int Orthopaed.* 2009;33(4):1113.
17. Agarwala S, Agrawal P, Sobti A. A novel technique of patella fracture fixation facilitating early mobilization and reducing re-operation rates. *J Clinic Orthopaed Trauma.* 2015;6(3):207-11.
18. Us AK, Kinik H. Self-locking tension band technique in transverse patellar fractures. *Int Orthopaed.* 1997;20(6):357-8.
19. Agarwala S, Agrawal P, Sobti A. A novel technique of patella fracture fixation facilitating early mobilization and reducing re-operation rates. *J Clinic Orthopaed Trauma.* 2015;6(3):207-11.
20. Ong TK, Chee EK, Wong CL, Thevarajan K. Fixation of comminuted patellar fracture with combined cerclage and tension band wiring technique. *Malaysian Orthopaedic J.* 2008;2(2):40-2.
21. Us AK, Kinik H. Self-locking tension band technique in transverse patellar fractures. *Int Orthopaed.* 1997;20(6):357-8.
22. Curtis MJ. Internal fixation for fractures of the patella. A comparison of two methods. *J Bone Surgery Br.* 1990;72(2):280.

23. Srinivas K, Surya PR, Narendranath L, Prasad RV. Evaluation of results of surgical treatment of closed #s of the patella. Ind J Orthop. 1984;38:104-6.
24. Depalma AF. Diseases of the knee. 3rd edn. Philadelphia. J. B. Lippincott; 1954:218.