



GALLBLADDER CANCER: CHARACTERIZING PRIMARY TUMOR AND NODAL SPREAD

Dr. Surendra Kumar Gupta¹, Dr. Astha Singh², Dr. Virendra Singh³, Dr. Gyan Prakash⁴

¹MD, Associate Professor, Department of Radiodiagnosis, MLN Medical College, Allahabad, UP, India.

²MD, Senior Resident, Department of Radiodiagnosis, MLN Medical College, Allahabad, UP, India.

³MD, Professor and Head, Department of Radiotherapy, MLN Medical College, Allahabad, UP, India.

⁴MSc, PhD, Assistant Professor, Department of community medicine, MLN Medical College, Allahabad, UP, India.

Conflicts of Interest: Nil

Corresponding author: Dr. Astha Singh

Abstract:

Objective: Presence of many surgico-pathological staging systems and acceptance of number of lymph nodes for deciding N stage in AJCC TNM 2010 staging system in gall bladder cancer may indicate suboptimal staging. Aim of the study is to assess the different radiological profile and corresponding lymph node spread using ultrasound and CT scan to propose a new radiological staging system.

Methods: This observational cross sectional study included 187 patients of histopathologically proven gall bladder carcinoma who underwent abdominal USG and CECT. Scans were evaluated for morphology of tumour, vascularity, loco-regional spread and nodes. The statistical analysis was done using IBM SPSS version 20.0. A two-sided chi-square test of association was applied for pattern of GB cancer and nodal spread. Additional role of CECT in addition to USG was assessed.

Result: There was definite female preponderance with female: male ratio of 2:1. In both sexes of age group 40 or more than 40 years had preponderance of imaging pattern of mass replacing gallbladder (36.7%). Lymph nodal spread occurred in 71.1% of cases with periportal being the initial site (97.74%). USG missed nodes in 12 patients which were detected on CECT. The frequency of lymph node involvement is strongly influenced by the depth of invasion of the primary tumor (52.8%).

Conclusion: CECT provides additional benefit from USG in assessing the nodal spread of gall bladder carcinoma. Having a radiological preoperative staging system will better define surgical technique/preoperative neoadjuvant or concurrent chemoradiotherapy schedule.

Keywords: Gallbladder, cancer, radiological, staging, lymph nodes

Introduction

Gall bladder cancer patients have advance stage at time of diagnosis and non surgical treatment options result in high mortality. Pathologists have major role in earlier staging systems of gall bladder cancer as evident by AJCC 2007 TNM staging dividing T1 stage into T1A (Tumor invades Lamina Propria) and T1B (Tumor invades muscle layer). This division could only be determined after surgery and as per AJCC 2010, TNM staging has abandoned this and replaced it by a single T1 category including tumor that has grown into Lamina propria or the muscle layer but this is also possible after histopathological examination. AJCC, TNM 2010 staging systems has N stage criteria which divides N stage to N1 (metastasis to 3 regional lymph nodes) and N2 (metastasis to 4 or more regional lymph nodes) based on number of Lymph nodes (1). Similarly other staging systems like Nevins's staging system have stages 1, 2 and 3 which can only be assigned after pathological examination (2). Capsular invasion determining stages 1, 2 and 3 of Japanese Biliary Surgical

Society staging system can only be determined after pathological examination.

Aim of this study was to assess the use of ultrasound in combination with CECT scan in pre-operative workup of gall bladder cancer and characterizing primary tumor and nodal spread. We also aimed to propose extensions in existing AJCC 2010 staging system so as to enable a preoperative radiological staging for optimal workup of patients.

Materials and Methods: This observational cross sectional study included 187 patients investigated both by abdominal USG and CT examination and eligibility criteria for inclusion was histopathologically proven (fine needle aspiration cytology or post operative specimen biopsy) proven cases of carcinoma gall bladder seen during the period of April 2012- April 2018. All the patients were subjected to USG evaluation first followed by contrast enhanced CT scan of whole abdomen. USG examination was performed using LOGIQ- P9 USG machine (GE Healthcare).

CT Scan was done on Multislice volume zoom CT 4 slice (Siemens, Germany). Initially plain axial scans were taken from the domes of diaphragm till the level of iliac crest, after administering 1000 ml of iodinated water soluble oral contrast (20ml of 350mg/ml non ionic water soluble contrast mixed with water to make 1000ml) with 800ml half an hour before examination and 200ml at the time of examination for bowel opacification. Scanning was performed using pitch of 1.0:1, a scanning time of 0.6 sec/rotation, table speed of 10 mm/rotation, 160-180 mAs, and 120 kVp. Later on contrast enhanced scan was done after administering 80-100 ml of non ionic water soluble contrast (350mg/ml) depending upon weight of the patient with pressure injector at a rate of 2.0ml/sec and scans were taken in portal venous phase (50-55sec after contrast initiation of contrast administration). Scans were taken from the domes of diaphragm till pubic symphysis. Images were acquired with slice thickness of 5mm and reconstruction interval of 0.7mm followed by multiplanar reconstruction (MPR) algorithm both in coronal and sagittal plane. Scans were evaluated in axial as well as in coronal and sagittal planes.

Image analysis of USG and CT of all cases was done by two radiologists with consensus reading. Scans were evaluated for morphology of tumour, vascularity, loco regional spread and nodes. Morphology of GB mass was further categorised into focal or diffuse asymmetric wall thickening, intraluminal mass at fungus, body or neck, mass replacing gallbladder with or without liver infiltration. Focal, irregular, asymmetric wall thickening of more than 3 mm with vascularity or enhancement was considered suspicious for malignancy. Intraluminal polypoidal mass was considered malignant if it showed vascularity, more than 1 cm in diameter with which base and did not change position with posture change of patient on real time USG scan(3). Presence of a large mass that replaces or fills the lumen of gallbladder which is heterogeneous, hypoechoic with colour flow on USG and hypodense and enhancing equal to or more than hepatic parenchyma on CECT was considered as malignant mass replacing GB. Lymph nodes involvement in periportal, celiac and retroperitoneal group were also assessed. Lymph nodes of size more than 1 cm in short axis was considered indicative of malignancy.

Vascular involvement and lymphadenopathy were assessed on CT scan as well as with Ultrasonography in subcostal oblique view of porta hepatis and through the hepatoduodenal ligament along with colour Doppler and spectral Doppler.

The statistical analysis was done using IBM SPSS version 20.0 statistical analysis software. Data was analysed according to staging by AJCC TNM staging 2010. Additional finding which were missed on USG but picked up by CT were recorded and compared by descriptive statistics. A

two-sided chi-square test of association was applied for contingency table analysis for pattern of GB cancer and nodal spread.

Results:

The patients presented with vague complaints of epigastric pain, abdominal pain, loss of appetite to clinically palpable lump abdomen and mostly with obstructive jaundice.

Our study showed definite female preponderance with female: male ratio of 2:1 with the gender ratio increasing from 2:1 below 60 years age to 4:1 in the peak incidence age group of 61-70 years (Table 1). The age of patients ranged from 20 to 88 years with a mean age of 55 years for both males and females (Table 1). Peak incidence of gall bladder cancer in female is seen in between 61-70 years age group and in males at 41-50 years age group. Prevalence of Gallbladder cancer increased with age up to 70 years (Figure1).

In both sexes of age group 40 or more than 40 years, we found preponderance of imaging pattern of mass replacing gall bladder, 19 out of 52 patients in male (36.5%) and 40 out of 111 patients in female (36.0%), followed by mass at GB neck in male (32.6%) and female(26.1%) patients(Table2).These radiological patterns in older age group , who are having other age related co morbidities are more likely to undergo non surgical treatment.

Table 3 revealed that periportal (cystic and pericholedochal lymph nodes) are the initial site of spread from gallbladder cancer. The frequency of lymph node involvement is strongly influenced by the depth of invasion of the primary tumor (52.8%). Out of 133 patients having significant lymphadenopathy , 56 patients(42%) had retroperitoneal nodal involvement as detected on CECT.However, USG detected lymph nodes in only 121 patients and missed retroperitoneal nodes in 9 patients(16%) and periportal nodes in 3 patients. Lymph nodal spreads were contiguous as the patients who were having retroperitoneal lymphadenopathy were almost always having periportal and celiac lymph node enlargement and the patient with celiac lymphadenopathy always had periportal lymphadenopathy. Individual celiac and retroperitoneal lymphnodal enlargement with periportal lymph node were uncommon (<1%).

Results showed a non-statistically significant association between age of 40 years and above and female gender having imaging pattern of mass replacing gall bladder and predominantly neck region mass (Figure 2) and these imaging patterns also spread more commonly to periportal, celiac and retroperitoneal lymph nodes which are difficult to resect. Lymph node spread was seen highest in mass replacing gall bladder(40.6%) followed by imaging pattern of mass at gall bladder neck (25.5%).

Table 1: Age and Sex distribution of patients.

Age Interval	Sex			
	Male	%	Female	%
30 & Below	3	1.60	2	1.06
31 -- 40	7	3.72	25	13.3
41 -- 50	17	9.04	25	13.3
51 -- 60	14	7.45	30	15.96
61 -- 70	8	4.26	33	17.55
71 & Above	10	5.32	13	6.91
Total	59		128	

Table 2: Relation of Sex/Age with imaging pattern of carcinoma gall bladder.

Imaging Pattern	Male			Female		
	Less than 40 Years Age	40 & Above Years Age	p-value	Less than 40 Years Age	40 & Above Years Age	p-value
Focal wall thickening of gall bladder	0	1	-	2	5	0.5136
Predominantly Intraluminal mass at fundus	0	6	-	1	21	0.3263
Predominantly Intraluminal mass at body	2	9	0.8403	4	15	0.4744
Predominantly Intraluminal mass at neck	3	17	0.9139	2	29	0.3255
Mass replacing gallbladder with liver infiltration	2	19	0.6794	8	40	0.3820
Polypoid mass in gallbladder without liver infiltration	0	0	-	0	1	-
Total No of cases	7	52		17	111	

Table 3: Imaging Pattern of carcinoma gall bladder versus region of Lymph Node Involvement.

Imaging Pattern	No of patients with lymph nodes	Periportal	P+C	P+C+R	C	C+R	P+R	R
Focal wall thickening	7	2		1			4	
Fundus	20	11	2	5	1			1
Body	18	9		5			4	
Neck	34	15	1	6		1	11	
Mass replacing GB with liver Infiltration	53	28	8	12			5	
Without infiltration	1			1				
Total no of patients with Lymph nodes	133	65	11	30	1	1	24	1

Table 4: Proposed extension of radiological TNM Staging of gallbladder cancer.

Tumor staging(T)	
T1	Focal irregular wall thickening of gall bladder.
T2	Focal mass in lumen of gall bladder.
T3	Tumor infiltrating adjacent liver parenchyma and/or other adjacent extra hepatic organs likes stomach, duodenum, colon, pancreas and extra hepatic bile ducts.
T4	Tumor invading main portal vein or hepatic artery or multiple extra hepatic organs.
Lymph nodes (N)	
N0	No lymph node.
N1	Metastasis to periportal and celiac lymph nodes.
N2	Metastasis to retroperitoneal lymph nodes.
Metastasis(M)	
M0	No metastasis.
M1	Distant metastasis.

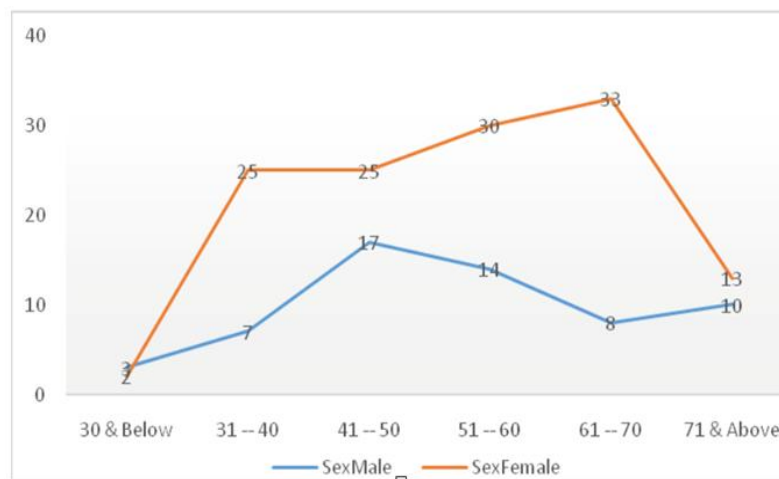


Figure 1: Comparison of incidence of gall bladder cancer according to age and sex.

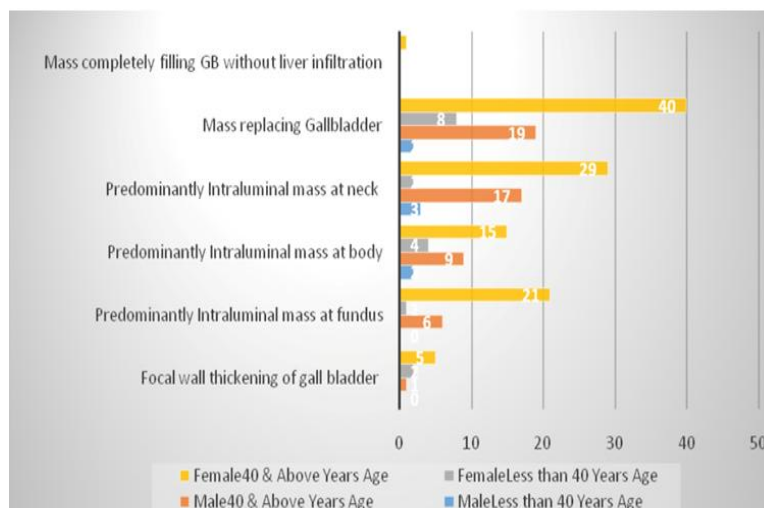


Figure 2: Relation of Age and Gender with incidence of imaging pattern of gall bladder

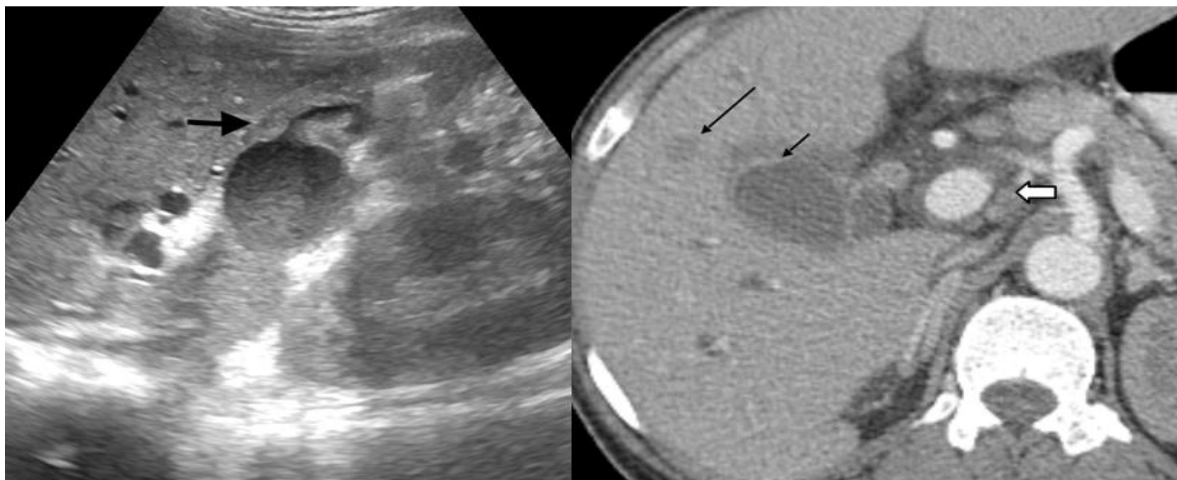


Figure 3a: 55 years old, male: Trans abdominal USG shows focal eccentric irregular hypoechoic wall thickening (black arrow) in fundus and body of gall bladder. No calculus is seen. **Figure 3b:** Contrast enhanced CT Scan of abdomen reveals focal eccentric irregular thickened enhancing wall in fundus and body of gall bladder (small black arrow), small mildly enhancing metastatic hepatic nodule (long black arrow) and enlarged periportal lymph nodes (small white arrow).

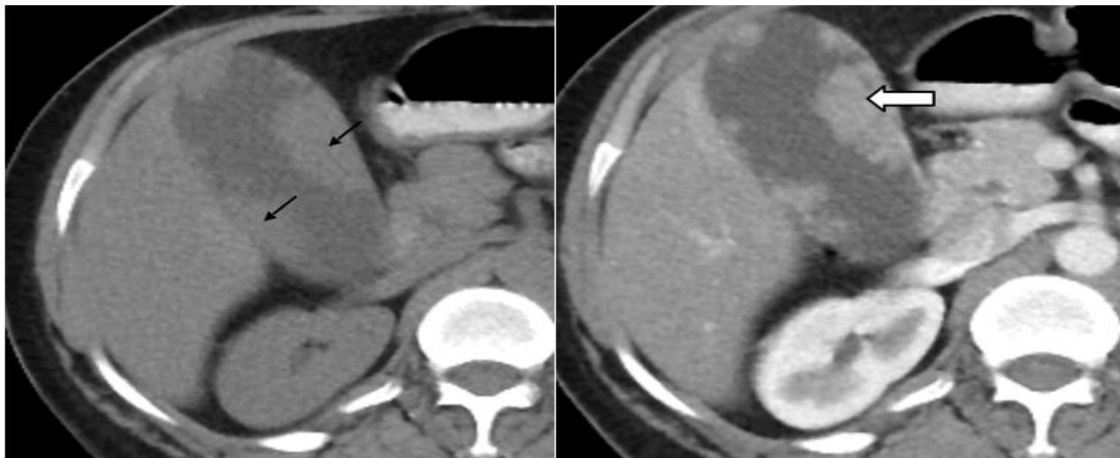


Figure 4a: 40 years old, female: Plain CT Scan abdomen shows multifocal small polypoidal intraluminal soft tissue lesions (black arrow) in fundus and body region, hypodense to liver and denser than bile. Figure 4b- Contrast enhanced CT Scan abdomen shows presence of multifocal small polypoidal intraluminal homogeneously enhancing soft tissue lesions (white arrow) in fundus and body of gall bladder.

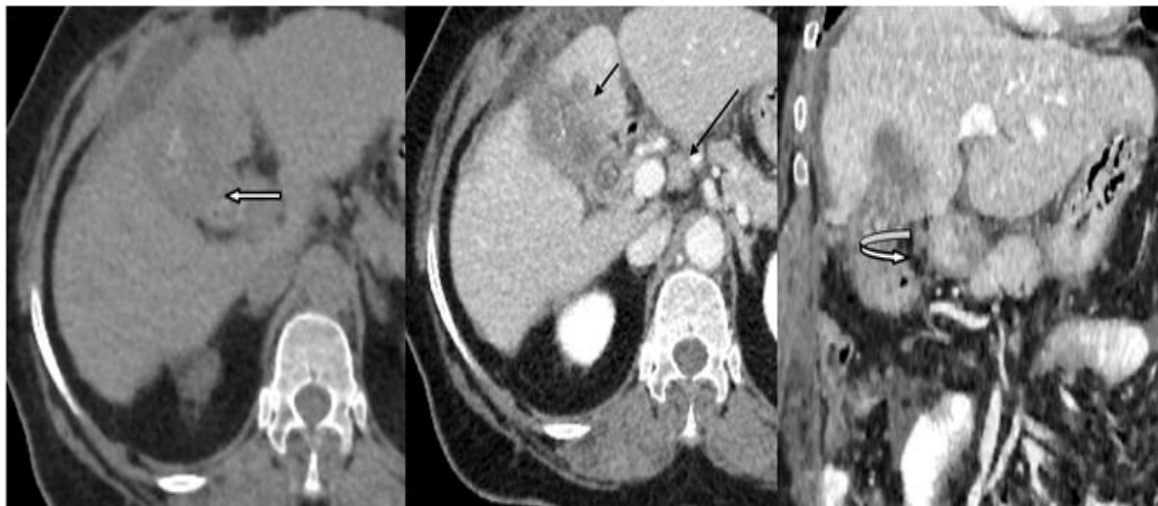


Figure 5a: 45 years old, female; Plain CT Scan abdomen; shows ill-defined irregular hypodense soft tissue mass replacing gall bladder with presence of two large intralesional hyperdense calculi (white arrow). Figure 5b- Contrast enhanced CT Scan abdomen; shows heterogeneously enhancing mass replacing gall bladder infiltrating adjacent liver parenchyma (black small arrow), enlarge periportal lymph nodes (long black arrow)) and omental infiltration. Figure 5 c- Contrast enhanced CT scan abdomen with coronal reconstruction shows better depiction of infiltration of hepatic flexure colon (curved white arrow).

Discussion:

Early diagnosis of gall bladder carcinoma is often missed due to presentation clinically. USG is a primary modality in catching the same in a developing nation with limited resources. However, as our study showed, USG missed 9% of significant lymph nodes overall and 16% of retroperitoneal lymphnodes in particular. These were readily detected on CECT. This study shows that CECT in addition to USG is able to determine primary tumor staging as well as lymph nodal staging.

Traditionally, paraaortic lymph node metastasis was a contraindication to surgical resection; however it is reported that resection in these patents confers a similar survival to those with isolated liver metastases and better survival than unresected tumors with other sites of metastatic spread. Contraindications to surgical resection in advanced tumors however remain poorly defined and as such each case should be evaluated on individual basis (4)

Regional lymph nodes of gallbladder cancer are classified based on nodes involved: N1-Cystic, pericholedochal and hilar lymph nodes, hepatoduodenal ligament lymph nodes.

N2-Peripancreatic (head only), periductal, periportal, common hepatic artery, celiac and superior mesenteric artery lymph nodes. Adequate assessment as per AJCC guidelines recommends resection and pathologic examination of a minimum of three regional lymph nodes (Cystic, pericholedochal, retroportal, periduodenal, peripancreatic, celiac and superior mesenteric nodes (5)

In our study lymph nodal spread occurred in 71.1% of cases at the time of diagnosis. Lymphatic spread is present in more than 50% of patients at initial diagnosis and first reaches cystic, pericholedochal, hilar, periduodenal, peripancreatic and superior mesenteric nodes, which are considered regional lymph nodes. Portocaval, interaortocaval, and more distant nodes are considered distant nodes in sixth edition of AJCC staging manual for gall bladder carcinoma (6).

In our study, we found that the patients who were having retroperitoneal lymphadenopathy were almost always having periportal and celiac lymphadenopathy and the patient with celiac lymphadenopathy always had periportal lymphadenopathy. Thus proving the contiguous nodal spread of gall bladder carcinoma and suggesting that cystic and pericholedochal lymph nodes are the initial site of spread from gallbladder cancer. The frequency of lymph node involvement is also strongly influenced by the depth of invasion of the primary tumor which is similar to work done by Tsukuda et al. (7). Detection of lymphadenopathy in the hepatoduodenal ligaments and the peripancreatic region is sensitive but not specific because not all large nodes may contain tumor tissue and microscopic deposits will be missed with all imaging techniques (8). The morphologic characterization of nodes are important. A flat lymph node with retention of the echogenic hilar stripe is more often reactive than are lymph nodes that are round and hypoechoic. The occurrence of lymph nodal metastasis alone does not contraindicate surgery because of lymphadenectomy of all lymph nodes that are potentially infiltrated by tumor is routinely performed. Non invasive preoperative staging is required for appropriate care of patients and has become more reliable as advances in CT, MRI and PET have occurred (3).

CT has an accuracy of up to 84% in determining T stage of Primary gall bladder carcinoma (9) and 85% in predicting respectability through its ability to delineate hepatic and vascular invasion, lymphadenopathy, and distant metastasis (10). CT is commonly performed as unenhanced and iodinated contrast enhanced studies during the hepatic arterial and portal venous phases, from which multiplanar and 3D volume-rendered reconstruction images may be generated to provide a vascular road map as well as coronal oblique images that are useful for surgical planning (10). The early radiologic detection of gall bladder carcinoma at a point where subtle morphologic

abnormalities state manifests and having a radiological preoperative staging system will better define surgical technique/preoperative neoadjuvant or concurrent chemoradiotherapy schedule and comparative response of various schedules. Nevins' staging (2) is based completely on pathological findings and Ultrasound plus CT imaging can not differentiate Nevins' stage 1 that is mucosal involvement from stage 2 that is mucosa plus muscularis and stage 3 having invasion of mucosa plus muscularis plus subserosa. Japanese Biliary Surgical Society staging system (11,12) has too many surgically assessed parameters for which corresponding preoperative radiological finding are difficult to evolve into radiological staging system.

The patterns of carcinoma gall bladder we found in our study were- A) Focal irregular wall thickening (4.2%; Fig. 3a and 3b), B) Focal mass predominantly Fundus (15%; Fig. 4a and 4b), body (16 %; Fig. 5a, 5b, 5c), Neck (27.2 %) and C) mass replacing gall bladder with liver infiltration (36.7%; Fig. 6a, 6b, 6c) and D) Polypoid mass in gallbladder lumen without liver infiltration (0.5%). This is comparable to patterns described by AJCC Cancer Staging Manual (1) on CT Scan- A) polypoid mass within gallbladder lumen (15-25%) B) Focal wall thickening C) diffuse wall thickening (20% gallbladder cancer and D) mass replacing the gallbladder (45-60%).

The cost effective approach of limiting laparoscopy/MRI/PET CT in USG and CT indeterminate cases is suitable in resource constraint situation. Patients with AJCC stage 1 to stage 2b can undergo surgical resection and T3 lesions are difficult to operate. T4 tumors are considered unresectable but 2 exceptions in the literature-A) if main portal vein invasion is present, then portal vein resection and reconstruction may be indicated rarely or B) If there is extensive extra hepatic organ involvement this may be resected en bloc (13).

External beam radiation therapy and systemic chemotherapy have improved survival in patients with negative resection margins, whereas patients with positive microscopic margins or residual disease show no added benefit from chemotherapy and are offered adjuvant radiotherapy only (14).

Although up to 60% of patients with gallbladder carcinoma who undergo extended resection may survive 5 years, the overall prognosis is only 13% (15). Preoperative chemoradiotherapy in 27 potentially resectable gallbladder cancer resulted in 7 patients being alive at median follow-up of 24 months (16,17).

For the last 9 years no change in staging has been done so proposed radiological staging along with FNAC of gall bladder lesion may result in adoption of better surgical technique and judicious application of chemoradiotherapy.

The early radiological detection of gall bladder carcinoma at a point where subtle morphologic abnormalities state manifests and having a radiological preoperative staging system will better define surgical technique/preoperative neoadjuvant or concurrent chemoradiotherapy schedule and comparative response of various schedules. In our opinion, AJCC 2010 Staging system (1) can be further extended by addition of radiological findings (Table 4), whereby T1 will be focal irregular wall thickening, T2 focal mass is seen in lumen of gallbladder; T3 tumors will show adjacent invasion of liver parenchyma and/or other adjacent organs like stomach, duodenum, colon, pancreas and extra hepatic bile ducts; T4 tumor invading main portal vein or hepatic artery or multiple extra hepatic organs. For nodal staging N0 –no regional lymph node metastasis; N1-metastasis to periportal and celiac lymph nodes, N2-metastasis to retroperitoneal lymph nodes. Distant metastasis will be assessed by PET with contrast CT; M0-no distant metastasis; M1 being distant metastasis.

Thus, we suggest a provisional scanning by USG followed by CECT in patients with suspicion of malignant lymphadenopathy as it can change the staging and affect the management course of patients. We also suggest to include radiological assessment of morphology of carcinoma gall bladder and location of nodal spread in existing and future staging systems; so as to provide a more comprehensive preoperative assessment of patients for optimum workup and help in suggesting the course of further management.

Conclusion:

CECT provides additional benefit from USG in assessing the nodal spread of gall bladder carcinoma. A provisional scanning by USG followed by CECT in patients with suspicion of malignant lymphadenopathy can be introduced as it can change the staging and affect the management course of patients. Periportal and celiac lymph nodes are the initial site of spread from gallbladder cancer. Lymph node involvement is influenced by depth of invasion of primary tumor.

Having a radiological preoperative staging system will better define nodal assessment and deciding surgical technique/preoperative neoadjuvant or concurrent chemoradiotherapy schedule.

List of Abbreviations:

AJCC - American Joint Committee on Cancer
 TNM- Tumor, Node, Metastasis
 USG- Ultrasonography
 CT- Computed Tomography
 CECT- Contrast Enhanced Computed Tomography
 MPR- multiplanar reconstruction

GB- Gall Bladder
 SPSS- Statistical Package for the Social Sciences

MRI- Magnetic Resonance Imaging

PET- Positron Emission Tomography

MDCT- Multi Detector Computed Tomography

References:

1. AJCC, Gallbladder in AJCC Cancer Staging Manual, Edge SB, Byrd DR, Compton CC et al. Springer, Newyork, NY USA 7th edition, 2010; pp211-217.
2. Nevin JE, Moran TJ, Kay S, King R. Carcinoma of gallbladder Cancer 1976;37(1):141-148.
3. Rodriguez-Fernandez A, Gomez-Rio M, Medina-Benitez A, et al. Application of modern imaging methods in diagnosis of gallbladder cancer. J Surg Oncol 2006; 93:650-664.
4. Nishio H, Nagino M, Ebata Y, Yokoyama Y, Igami T, Nimura Y. Aggressive surgery for stage 4 gallbladder carcinoma; what are the contraindications? Journal of Hepatobiliary-pancreatic surgery 2007;14(4):351-357.
5. Ilari DM, Iloward J II, Leung AM, Chui CG, Sim MS, Bilchik A J. A 21-year analysis of stage 1 gallbladder carcinoma: is cholecystectomy alone adequate. HPB 2013;15(1):40-48.
6. Greene FL, Flemming ID, Fritz A et al. AJCC Cancer staging manual, 6th ed. New York, NY:Springer, 2002:139-142.
7. Tsukada K, Kurosaki I, Uchida K, Shiraj Y, Oohashi Y, Yokoyama N, Watanabe H, Hatakeyama K. Lymph Node Spread from Carcinoma of the Gallbladder Cancer 1997;80:661-7.
8. Carl M Bloom, Bernard Langer, Stephanie R Willson. Role of US in the detection, Characterization and staging of cholangiocarcinoma. Radiographics 1999;19 (5):1199-1218.
9. Kim SJ, Lee JM, Lee JY, et al. Accuracy of preoperative T-staging of gallbladder carcinoma using MDCT. AJR 2008;190:74-80.
10. Kalra N, Suri S, Gupta R, et al. MDCT in the staging of gallbladder carcinoma. AJR 2006;186:758-762.
11. Lai CHE, Lau WY. Gallbladder cancer-a comprehensive review Surgeon 2008;6(2):101-110.
12. Onoyama H, Yamamoto M, Tseng A, Ajiki T, Saitoh Y. extended cholecystectomy for carcinoma of the gallbladder. World Journal of Surgery 1995;19(5):758-763.
13. Miller G and Jarnagin WR. Gallbladder carcinoma, European Journal of Surgical Oncology. 2008; 34(3): 306-312
14. Kresl JJ, Scild SE, Hennin GT, et al. Adjuvant external beam radiation therapy with concurrent chemotherapy in the management of gallbladder carcinoma. Int J Radiat Oncol Biol Phys 2002;52:167-175.

15. Ito H, Matros E, Brook DC, et al. Treatment outcomes associated with surgery for gallbladder cancer: a 20 year experience. J Gastrointest Surg 2004;8:183-190.
16. Aretxabala X de, Burgos L, Roa Ivan, Cartes R. Preoperative chemoradiotherapy in treatment of gallbladder cancer. The American surgeons 1999;65(3):241-6.
17. Deshmukh S D, Johnson P T, Sheth S, Hruban R, Fischman E K. CT of Gallbladder cancer and Its mimics: a pattern based approach. Abdominal imaging 2013;38 (3): 527-536.