



## COMPARATIVE EVALUATION OF RADICULAR DENTINE THICKNESS IN DANGER ZONE OF MANDIBULAR FIRST MOLAR AFTER INSTRUMENTATION WITH TWO DIFFERENT ROTARY SYSTEMS USING CBCT - AN INVITRO STUDY

Dr. Ambika Sigadam<sup>1</sup>, Dr. Kalyan Satish R<sup>2</sup>, Dr. Girija. S. Sajjan<sup>3</sup>, Dr. Madhu Varma K<sup>4</sup>, Dr. Kolla Vishal Babu<sup>5</sup>, Dr. Sirisha Ganguru<sup>6</sup>

<sup>1</sup>Postgraduate Student, Department of Conservative Dentistry and Endodontics, Vishnu Dental College and Hospital, Bhimavaram, Andhra Pradesh, India.

<sup>2</sup>MDS, Professor, Department of Conservative Dentistry and Endodontics, Vishnu Dental College and Hospital, Bhimavaram, Andhra Pradesh, India.

<sup>3</sup>MDS, Professor and Head of the Department, Department of Conservative Dentistry and Endodontics, Vishnu Dental College and Hospital, Bhimavaram, Andhra Pradesh, India.

<sup>4</sup>MDS, Professor, Department of Conservative Dentistry and Endodontics, Vishnu Dental College and Hospital, Bhimavaram, Andhra Pradesh, India.

<sup>5</sup>Postgraduate Student, Department of Conservative Dentistry and Endodontics, Vishnu Dental College and Hospital, Bhimavaram, Andhra Pradesh, India.

<sup>6</sup>MDS, Private Practice, Guntur, Andhra Pradesh, India.

**Conflicts of Interest:** Nil

**Corresponding author:** Dr. Ambika Sigadam

**DOI:** <https://doi.org/10.32553/ijmsdr.v4i8.643>

### Abstract:

**Introduction:** The mandibular first molar poses a series of anatomic challenges such as multiple canals, isthmuses, lateral canals, and apical ramifications. Additionally, the distal surface of mesial root presents a thin zone, which is 4-6 mm cervical to canal orifice with a thin area of dentin termed as “danger zone,” as it increases the risk of perforation of furcal dentin during mechanical instrumentation.

**Aim:** To measure the amount of the dentin removed after biomechanical preparation with XP-Endoshaper and Neoendo flex files in the danger zone of the mandibular first molar using CBCT.

**Methodology:** Twenty-four mandibular first molars, the mesial roots of which presented a curvature of 20-30 degrees, were selected using the Schneider method. Samples were instrumented with Neoendo rotary file system (n=12) and XP-Endoshaper rotary single file system (n=12). The samples were scanned using CBCT before and after instrumentation. The analyzed parameter includes the remaining dentin thickness at the danger zone of the mandibular 1<sup>st</sup> molar. The obtained data were subjected to statistical analysis.

**Results:** There was no significant difference in remaining dentine thickness between the two rotary systems ( $p > 0.05$ ).

**Conclusion:** XP-Endoshaper revealed better results than Neoendo rotary files. However, both rotary file systems showed no significant difference in the remaining dentin thickness in the danger zone of the mandibular first molar.

**Keywords:** Danger zone, Remaining dentine thickness, XP EndoShaper, NeoEndo, CBCT.

### Introduction:

Thorough knowledge of the root canal anatomy is essential for successful endodontic therapy.<sup>(1)</sup> The mandibular first molar being the most frequently endodontically treated tooth<sup>(2)</sup>, also poses a series of anatomic challenges. These complexities include multiple canals, isthmuses, lateral canals, and apical ramifications.<sup>(3)</sup> Additionally, the distal surface of the mesial root presents with a thin area of dentin termed a “danger zone” because of the increased risk of perforation of furcal dentin in this area during mechanical instrumentation.<sup>(4)</sup> The danger zone has been described as 4 to 6 mm cervical to the canal chamber orifice.<sup>(5)</sup> The average thickness for the danger zones of the mesial roots was 0.789 +/- 0.182mm.<sup>(6)</sup>

The goal of biomechanical preparation is to remove the

bacterial debris from the root canal system thoroughly and provide proper space for the gutta-percha. During this preparation, radicular dentine harboring the bacteria has to be removed while preserving the dentine in vulnerable areas like the danger zone.

Neoendo Flex Files (Neoendo, London, England)(NE) is a newer NiTi Rotary File system, with Gold thermal treatment, which demonstrates special properties like extreme flexibility, safety tip, the triangular cross-section with sharp cutting edges.<sup>(7)</sup>

A recently introduced single file system known as the XP-Endo Shaper (XPS) (FKG Dentaire, La Chaux-de-Fonds, Switzerland) uses a rotary NiTi snake-shaped instrument. As claimed by the manufacturer, it has a canal adaptive property leading to minimum removal of dentine during biomechanical preparation.

Cone Beam Computed Tomography (CBCT) is a diagnostic imaging modality that provides high-quality, accurate three-dimensional (3D), which gives the accurate thickness of the radicular dentin.<sup>(8)</sup>

There is no abundant literature available regarding the remaining dentine thickness at the danger zone using different rotary systems. Hence this study was designed to compare the amount of dentine remaining in danger area using XP- Endoshaper and NeoEndo flex files in mandibular first molars using CBCT.

The null hypothesis of this study was that there would be no difference in remaining dentin thickness when XP- Endoshaper and NeoEndo flex files were used in the danger zone of mandibular first molars using CBCT.

### Materials and methodology:

Fifty human mandibular molars were collected, rinsed with distilled water, and stored in physiologic saline to prevent dehydration until their use at room temperature. Hard and soft tissue debris was removed with an ultrasonic scaler. Mesial roots of mandibular molar teeth with two canals with completely formed apices and curvature between 20° to 30° degrees by Schneider's method were included in this study. Teeth with anomalies, caries extending onto the root surface, previously endodontically treated teeth, calcified canals, and teeth with curvature less than 10° degrees were excluded.

Sample size calculation: Estimated on the basis of the remaining dentin thickness using "G\*Power" v3.0.1 software was used to estimate the sample size for 1-way ANOVA. The sample size actually obtained for this study was 12 teeth for both the groups. So a total of 24 teeth (Group I- Neo-Endo File, Group II-XP- Endoshaper) were included in the study.<sup>(9)</sup>

The access cavity was prepared using Endo access bur (Dentsply/Maillefer, Switzerland). The working length (WL) was estimated 1 mm short of apex. All specimens were vertically sectioned with the double-faced diamond disc and separated from distal roots. Teeth were randomly divided using computer-generated randomization into two groups (n=12) and were embedded in the horseshoe-shaped modeling wax rim.<sup>(10)</sup>

Scanning procedure: All teeth were initially scanned by using the CBCT system. The images were captured at 90-120 kVp and 10mA with a 90µm voxel size and exposure time of 1.6 sec to determine dentine thickness in mesiobuccal canals before instrumentation. For each section, the following measurement was made Y1.

Group-I (12 samples): Glide path was prepared with 15 K-file. The Neoendo files (tip size = 20#, 25#, 30#, taper = 0.04) were used in a full clockwise rotation with a rotational

speed of 350 rpm and torque of 1.5 N/cm generated by the X-Smart motor (Dentsply Maillefer). The files were used in a slight pecking motion until they reach the working length. RC Prep was used as a lubricant in all canal preparations. The canal irrigation protocol followed was 3% NaOCl and 17% EDTA with intermittent distilled water rinse using a syringe with a 27-gauge needle.

Group-II (12 samples): Glide path was prepared with 15 no K-file. Root canals were prepared by using XP-Endo Shaper (FKG Dentaire SA, Chaux-de-Fonds, Switzerland) 30/0.04 upto working length, powered by similar electric torque control motor X-Smart motor with a speed of 800 rpm. Similar irrigation protocol as in Group I was followed in Group II.

Post Instrumentation Scan: After preparation, CBCT scans were performed. The instrumented canals were scanned with the SINORA CBCT system incorporated with OnDemand software using the same protocol and parameter settings. Brightness, contrast, and sharpness settings were standardized for pre and post instrumentation scans. For each section, the following measurement was made Y2.

Assessment of Root Canal Preparation: All the samples were evaluated in axial view at 4mm from the CEJ in both preoperative and postoperative scanning procedures. The shortest distance from the edge of the canal to the periphery of the root (distal) was measured on the reconstructed cross-sectional images of the pre and post instrumentation scans by using the measuring tool.

Y1 is the shortest distance from the distal edge of the root to the distal edge of the uninstrumented canal

Y2 is the shortest distance from the distal edge of the root to the distal edge of the instrumented canal<sup>(11)</sup>, as shown in Fig 1.

Data was collected and tabulated for statistical analysis. Statistical analysis was performed using the Statistical Package for Social Sciences (SPSS), version 24.0.

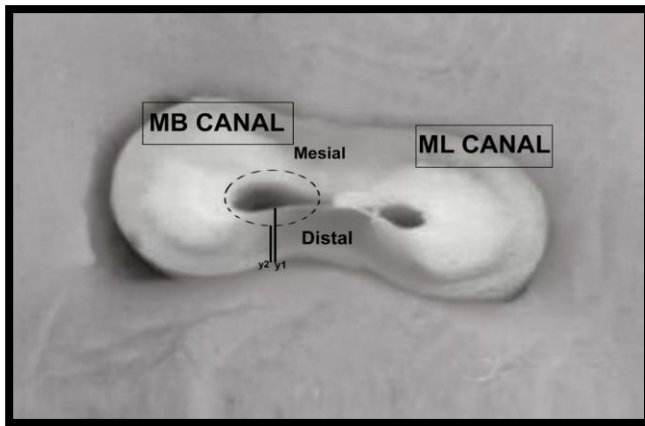
### Results:

Table 1-shows the remaining dentin thickness of file systems at 4mm from the CEJ of mandibular first molars. It was inferred that NE preoperative with a mean value of 1.1350 mm and postoperative with a mean value 0.31223 mm and change in remaining dentin thickness in NE group was with a mean difference of 0.21129. XP EndoShaper preoperative with a mean value of 0.28646 mm and postoperative with a mean value 0.26466mm and change in remaining dentin thickness in the XP Endoshaper group with a mean difference of 0.2658. However, a p-value of 0.927, as analyzed by Kruskal Wallis ANOVA, suggests that there was no significant difference between the two

groups.

**Table 1:** Remaining dentin thickness of file systems at 4mm from the CEJ of mandibular first molars.

	GROUP	n	MEAN	SD	T value	p-value
PREOPERATIVE	NE	12	1.1350	.3898	1.593	0.125
	XP	12	0.9125	.2864		
POSTOPERATIVE	NE	12	0.8617	.3122	1.820	0.082
	XP	12	0.6467	.2646		
CHANGE IN RDT	NE	12	0.2733	.2112	0.093	0.927
	XP	12	0.2658	.1836		



**Figure 1:** Schematic diagram of representing Remaining dentine thickness measurement before and after Biomechanical prepa

#### Discussion:

The mandibular first molars have complex internal anatomy with major variations in the mesial roots. The canals in the mesial root are not located in the center of the root. Hence dentin present between the canal and furcation area is very thin. In the mesiobuccal canal comparatively, less dentine is present between the distal surface of the canal and furcation area ( $1.19\text{mm}^3$ ) than in the mesiolingual canal ( $1.25\text{mm}^3$ ).<sup>(12)</sup>

Chemo-mechanical preparation is essential for successful endodontic treatment. Most instrumentation techniques adopt a flare preparation of the cervical third. However, excessive flaring might lead to undesirable episodes as transportation of the preparation into the danger zone, or even strip perforations of the root.<sup>(10)</sup>

Traditional endodontic instruments are manufactured from straight metal blanks often fail to achieve Schilder's mechanical objectives as most canals are curved. This result in uneven force distribution in certain contact areas and over-prepare toward the outer curve or the convexity of the canal, whereas more coronal areas are transported toward the concavity.

RDT designates the instrumentation limits mechanically to widen the root canal diameter, to predetermined values

that would not weaken the root remarkably.<sup>(13)</sup> The remaining dentin thickness after the root canal procedure is directly related to the strength of the root, and the thickness of the dentinal wall at the root circumference is critical. Direct correlation exists between the root thickness and the ability of the tooth to resist lateral forces and avoid fracture.<sup>(14)</sup> So, the thinner the dentin, the more likely the tooth is to fracture.<sup>(15)</sup> Any false presumption regarding the root canal wall thickness may lead to complications like strip perforation and vertical root fracture. These are all the possible consequences due to the removal of excess dentin from the root canal wall.<sup>(16)</sup> Some authors recommended flaring the coronal third of the root canal to allow better access further into the middle and apical areas.<sup>(17)</sup> Nevertheless, too much flaring reduces the fracture resistance of the root that results in the likelihood of stripping and vertical root fracture.

NE is a 3rd Generation Rotary File. In the present study, 4%20, four %25, 4%30 were used. NE has cyclic fatigue resistance with a triangular cross-section with sharp cutting edges, which increases cutting efficiency. Safety tip, which is non-cutting, avoids accidental apical transportation. The extreme flexibility of these instruments favor the negotiation of any canal. NE has undergone a specialized heat treatment process, which gives them unique flexibility characteristics, and flutes do not open up when stress levels are reached, yet the file does not present shape memory.<sup>(18)</sup>

XPS is a new single-file system introduced to simplify instrumentation protocols. Made with MaxWire alloy, it offers remarkable flexibility, fatigue resistance, the ability to progress within the canals with ease and agility, and the property of expanding and contracting according to the canal morphology.

The Booster Tip (BT) of XPS benefits from a unique geometry, having six cutting edges at the tip. It enables the instrument to start shaping an ISO diameter smaller than NE. In the case of the XPS, the BT enables it to start shaping after a glide path of at least ISO 15, and to gradually increase its working field to achieve an ISO 30.

XPS easily adapts into the canal and, thus, apply constant delicate pressure on the canal walls, which allows for uniform removal of dentin along the whole perimeter of the root canal cross-section.

It has the ability to start shaping at ISO diameter 15 and achieves ISO diameter 30; also, it increases the taper from .01 to at least .04. It allows reaching the final canal preparation of a minimum of 30/.04, and this is achieved only with one instrument. The continuous rotation at high speed (800 rpm) and minimal torque ensure: Minimal stress is applied to the dentine walls, and the risk of micro-cracks in the dentine is minimized due to support from the

spring action against the walls. Due to its characteristics, the XPS enables the stress applied to the instrument and the canal walls to be restricted.

In the present study, a sample of 24 extracted mandibular molars with a variable dentin structure is to reproduce conditions close to the clinical situation.<sup>(19)</sup> For maintaining the homogeneity of the sample, the teeth having curvature between 20-30° were included. To determine the canal curvature, the Schneider method, which was the first and still most common method was used in the present study.<sup>(20)</sup>

The mesiobuccal canal was evaluated in this present study as they are more prone to strip perforation when compared to the mesiolingual canals due to the less amount of dentine present towards their distal surface of the root.<sup>(12)</sup> Later all the teeth were embedded into the modeling wax rim as they allow X-rays to pass through it and produce a better image quality and also to stabilize the teeth in the same angulation during preoperative and postoperative scanning.<sup>(18)</sup>

Evaluation of remaining dentin thickness in the root canal after biomechanical preparation can be performed with different methodologies, i.e., the radiographic platform with superimposing images of before and after instrumentation, muffle system, and CBCT. The major disadvantages of the radiographic platform with superimposing technique are technique sensitivity. The major disadvantages of the muffle system are the necessity to fabricate individual stone muffles for each tooth and the brittleness of the die stone.

CBCT, which is a recent advancement of CT in which the images can be analyzed with software that does not interfere with the original format of the images (DICOM). CBCT permits the analysis of the remaining dentin thickness by CT scans obtained in voxels, which in turn can be used for three-dimensional analysis.<sup>(21)</sup> Presently, it is the widely used tool to measure canal aberrations because it does not require the destruction of the specimen. Hence CBCT was used as a tool to assess the remaining dentin thickness in the present study.

In the present study, XPS showed less amount of dentin removal than the NE group. This was attributed to its design features and motion of instrumentation of XPS with an initial taper of .01. XPS expands once inside the canal, achieving a taper of at least .04. The Booster Tip (BT) in XP-Endo Shaper benefits from a unique geometry, having six cutting edges at the tip expanding and contracting according to the canal morphology.

The mean difference of dentine removed after instrumentation with NE was 0.2733, and XPS was 0.2658, with no statistical difference between the two groups. The

probable reason might be, though XPS is available with 30/.01 taper, completes the root canal with the preparation of 30/.04 taper, whereas NE is directly available as 30/.04 taper. Hence both the files might have removed an equal amount of dentine from the danger zone.

These results were consistent with that of the previous study done by Anil.k.et al, where NE has removed more dentine when compared to REVO-S in mandibular premolars.<sup>(10)</sup>

XPS is a single file system which removes dentine, with fewer chances of file separation and consumes less time for preparation when compared to NE which is available as multiple file system. XPS is also cost-effective.

Limitations of the present study: Though CBCT is cost-effective; the resolution is lower than the Micro CT. The Voxel size of CBCT used in this study was 90 micrometers, but Micro CT provides a 10-micrometer voxel size. With this Voxel size, the RDT can be better evaluated.

Further ex-vivo and in-vivo studies are needed with a larger sample size, in teeth with severe root curvatures to confirm these results in a clinical scenario.

#### Conclusion:

Among the tested rotary file systems, the XP Endo shaper showed better results when compared to Neoendo rotary files. However, there was no significant difference in the remaining dentine thickness in the danger zone of the mandibular first molar.

#### References:

1. Deutsch AS, Musikant BL. Morphological measurements of anatomic landmarks in human maxillary and mandibular molar pulp chambers. *J Endod.* 2004 Jun;30(6):388–90.
2. Hull TE, Robertson PB, Steiner JC, et al. Patterns of endodontic care for a Washington state population. *J Endod* 2003; 29:553–6.
3. DeDeus QD. Frequency, location, and direction of the lateral, secondary, and accessory canals. *J Endod* 1975; 1:361–6.
4. Berutti E, Fedon G. Thickness of cementum/dentin in mesial roots of mandibular first molars. *J Endod* 1992; 18:545–8.
5. Keesler JR, Peters DD, Lorton L. Comparison of the relative risk of molar root perforations using various endodontic instrumentation techniques. *J Endodon* 1983;9:439-47.
6. Garcia Filho PF, Letra A, Menezes R, Carmo AM. Danger zone in mandibular molars before instrumentation: an in vitro study. *J Appl Oral Sci.* 2003;11(4):324-6.
7. Ajmal Mir D, Sajad M, Farooq R, Purra AR, Ahangar FA. To evaluate the effectiveness in root canal disinfection of three rotary file systems: An in-vitro study. *Int J App Dent Sci.* 2018; 4(1): 225-227.
8. Durack C, Patel S. Cone beam computed tomography in endodontics. *Braz dent J.* 2012;23(3):179-91.
9. Rashmi Bansal, Mohan Gundappa, Sahil Dhingra. Danger zone: continuous versus reciprocatory University *J Dent Scie* 2016; 2(1),15-20
10. Tomer AK, Miglani A, Chauhan P, Nagarjuna P, Rana S, Kumari A. An in-vitro evaluation of remaining dentine thickness through

- Cbct using different files. IOSR J Dent Med Sci. 2017; 16:121-4.
11. Barker BCW, Parsons KC, Mills PR, Williams GL (1974) Anatomy of root canals. III. Permanent mandibular molars. Aust Dent J.19, 408–13.
  12. Rao MS, Shameem A, Nair R, Ghanta S, Thankachan RP, Isaac JK. Comparison of the remaining dentin thickness in the root after hand and four rotary instrumentation techniques: an in vitro study. J Contemp Dent Pract. 2013; 13(7);12–7.
  13. Plotino G, Grande NM, Falanga A, Di Giuseppe IL, Lamorgese V and Somma F. Dentine removal in the coronal portion of root canals following two preparation techniques. Int Endod J. 2007; 40: 852-8.
  14. Sathorn C, Palamara JE, Palamara D, Messer HH. Effect of root canal size and external root surface morphology on fracture susceptibility and pattern: a finite element analysis. J Endod.2005;31:288-92.
  15. Tabrizzadeh M, Reuben J, Khalesi M, Mousavinasab M, Ezabadi MG. Evaluation of radicular dentin thickness of danger zone in mandibular first molars. J Dent (Tehran). 2010; 7:196-9.
  16. Schilder H. Cleaning and shaping the root canal. Dent Clin North Am 1974; 18:269-96.
  17. Berutti E, Fendon G. Thickness of cementum/dentin in mesial roots of mandibular first molars. J Endodon 1992;18(11):545-8.
  18. Assmee, M. Comparative evaluation of remaining dentinal thickness after protaper next, neoendo flex, Mtwo rotary files preparation using CBCT: An In Vitro study. Master's thesis, Tamilnadu Government Dental College and Hospital, Chennai.2018
  19. Santa Rosa J, de Sousa-Neto MD, Versiani MA, Nevares G, Xavier F, Romeiro K, Cassimiro M, Leoni GB, de Menezes RF, Albuquerque D. Shaping Ability of Single-file Systems with Different Movements: A Micro-computed Tomographic Study.Iran Endod J. 2016;11(3):228-33.
  20. Yoo YS, Cho YB. A comparison of the shaping ability of reciprocating NiTi instruments in simulated curved canals. Res Dent Endodontics. 2012; 37(4):220-7.
  21. Aguiar CM, Donida FA, Camara AC, Frazao M. Cone beam computed tomography: a tool to evaluate root canal preparations. Acta Stomatol Croat. 2012; 46(4): 273-9.