



CBCT EVALUATION OF PERICERVICAL DENTIN THICKNESS AFTER COMPLETION OF BIOMECHANICAL PREPARATION WITH FIFTH GENERATION ROTARY FILES

Dr. Chutty Issac¹, Dr. Kusum Valli S², Dr. Shiraz Pasha

¹Postgraduate student, Department of Conservative Dentistry and Endodontics, Sri Rajiv Gandhi College of Dental Sciences and Hospital, Bangalore.

²MDS, Professor and Head of the Department, Department of Conservative Dentistry and Endodontics, Sri Rajiv Gandhi College of Dental Sciences and Hospital, Bangalore.

³MDS, Professor, Department of Conservative Dentistry and Endodontics, Sri Rajiv Gandhi College of Dental Sciences and Hospital, Bangalore.

Conflicts of Interest: Nil

Corresponding author: Dr. Chutty Issac

DOI: <https://doi.org/10.32553/ijmsdr.v4i8.644>

Abstract:

Aim and objectives: The purpose of this invitro study was to determine the effect of biomechanical preparation by fifth generation rotary files on the pericervical dentin thickness in mandibular molars.

Methods: 30 human mandibular molars with fully formed apices were used for this study.

Preoperative CBCT scans were made for each sample and PCD thickness was measured.

The teeth were divided into 3 groups of 10 teeth each.

Group 1: One Shape

Group 2: Protaper Next

Group 3: Revo S

Root Canal Preparation was done for all the specimens in each group.

Post instrumentation CBCT scans were made for each sample and PCD was measured.

Results: There was significant loss of PCD following root canal instrumentation with fifth generation rotary files. Highest remaining pericervical dentin thickness was found in Group III (Revo S), followed by Group I(One Shape) and Group II(Protaper Next).

Conclusion: Within the limitations of this study, it was concluded that there was significant loss of pericervical dentin following root canal instrumentation using fifth generation rotary files. Among the three groups, Revo S showed least amount of dentin removal followed by One Shape and Protaper Next.

Keywords: Biomechanical preparation, fifth generation rotary files, pericervical dentin

Introduction:

Long term success of endodontic treatment depends on many factors like minimally invasive preparations, irrigation, disinfection, restorations and the amount of tooth structure preserved.^[1] Of all these factors, the amount of pericervical dentin thickness is the most critical factor for the fracture resistance of endodontically treated teeth.^[2] Studies have reported that fracture of endodontically treated teeth is associated with loss of tooth structure due to dentinal caries, access preparation and root canal preparation.^[3] Though the influence of remaining tooth structure on fracture resistance is evaluated by many researchers^[4], however, only few studies have quantified the amount of tooth structure removed after completion of root canal preparation.

Hence the purpose of this study was to determine the effect of biomechanical preparation by fifth generation rotary files, on the pericervical dentin thickness in mandibular molars.

Aims and Objectives

The aim of this invitro study was to determine the effect of biomechanical preparation using three different Niti file system of fifth generation – Protaper Next, Revo S and One Shape on the pericervical dentin thickness in mandibular molars.

Materials and Methodology

The study protocol was approved by the ethical committee of Sri Rajiv Gandhi College of Dental Sciences and Hospital Bangalore. 30 human mandibular molars with fully formed apices were used for this study. The teeth were cleaned of superficial debris, calculus, tissue tags and all the teeth were radiographed using RVG to verify the inclusion and exclusion criteria

Inclusion Criteria:

- Human mandibular molars with complete root formation which were extracted for periodontal purposes, with mature apices were included.

Exclusion Criteria:

- Fractured teeth, carious teeth, teeth with incompletely formed apex, cracked teeth, teeth with internal or external resorption, teeth with root canal calcification or obstruction, teeth with pulpstone, previous restorations or endodontic manipulation, cervical abrasions and teeth with hypoplasia were excluded.

The teeth were decontaminated by immersion in 5.25% sodium hypochlorite for 30 min. Teeth were then stored in sterile normal saline 0.9% at room temperature.

Preoperative CBCT scans:

A customized template was made to standardize the position and angulations of the specimens for the CBCT scans (Fig.a). Preoperative CBCT scans were made for each sample (Exposure Parameters - 65 Kvp, 4mA, FOV-8X5cm, VOXELSIZE-90 μ m) and pericervical dentin thickness was measured 4mm above and below CEJ. The images were stored. Measurements were made using CS 9300 Imaging Software. (Fig.b)

The pericervical dentin thickness was calculated as the shortest distance from the canal outline to the closest adjacent root surface, which was measured in four surfaces that is facial, lingual, mesial, and distal for all the sample teeth.

Below CEJ the measurements were made on all these four aspects around each root.

Biomechanical preparation

Endodontic access cavities were prepared using Endo-Access bur (DentsplyMaillefer) in a high-speed hand piece. (Fig.c) The working length was determined using a 10 K file until it was visible at the apical foramen and recorded 1 mm less than this length. (Fig.d) The teeth were divided into 3 experimental groups of 10 teeth each.

GROUP- 1 [One Shape]:

A One Shape file having a size 25 at the tip and a taper of 0.06 was used with a rotational speed of 400 rpm and the torque adjusted to 2.5 Ncm with an endodontic motor in clockwise rotation. When apical resistance was encountered, the instrument was removed and cleaned, and the root canal was irrigated.

GROUP- 2 [Protaper Next]:

Glide path files P1 and P2 were used. PTN files were used in the sequence X1, X2 with an endodontic motor at 300 rpm and 2 Ncm torque according to the manufacturer's instructions using a gentle in and out brushing motion. The

instrumentation sequence was size 17, .04 taper and size 25, .06 taper respectively.

GROUP- 3 [Revo S]:

Revo S files were used with an endomotor at a rotation speed of 400 rpm and 1.2 Ncm torque. The files were used in the sequence of SC1, SC2 and SU with size 25, .04 taper; size 25, .06 taper and size 25,.06 taper respectively.

For all groups, a total volume of 2 ml of 0.9% NaCl solution was used for each root canal as an endodontic irrigant. The irrigant was delivered by 5ml (27 gauge) disposable plastic syringes. (Fig.e)

Post instrumentation CBCT scans:

Post instrumentation CBCT scans were made for each sample and pericervical dentin thickness was measured 4mm above and below CEJ. The images were stored. Measurement were made using CS9300 Imaging Software. Measurements were made on the buccal, lingual, mesial and the distal aspects. Below CEJ the measurements were made on all these four aspects around each root. (Fig.f,g)

Results

Comparison of mean pericervical dentin thickness before and after biomechanical preparation within each group was done using Repeated Measures of ANOVA test followed by Bonferroni's post hoc Analysis.

- On the mesial roots of the teeth, each group demonstrated a significant reduction in the Buccal, Lingual, Mesial and Distal sides at $P < 0.001$, except for group 3 in the mesial side [$P = 0.70$]. The mean pericervical dentin thickness post instrumentation on the mesial roots were 1.78+/-0.44 for group I, 1.58+/-0.56 for group II and 1.95+/-0.54 for group III. [Graph I]
- The distal roots showed a significant reduction in the mean pericervical dentin thickness in Buccal, Lingual, Mesial and Distal sides in each study group at $P < 0.001$, except for group 3 in the distal side [$P = 0.70$]. Mean pericervical dentin thickness on the distal roots for group I was 1.74+/-0.46, for group II was 1.70+/- 0.47 and 1.90+/-0.54 for group III. [Graph II]

The percentage of remaining dentin thickness as compared to the original dentin was calculated and comparison of mean percentage reduction in pericervical dentin thickness between the three groups after each stage of the study was done using One-way Anova test followed by Tukey's HSD post hoc analysis.

- The mean percentage reduction of pericervical dentin thickness of the mesial roots, from pre to post instrumentation was significantly different between the three study groups on distal side at $P = 0.01$. Multiple comparison between groups revealed that group 3 showed

significantly lesser mean percentage reduction in pericervical dentin thickness as compared to group 2 at $P=0.01$. Mean percentage reduction of pericervical dentin thickness was calculated as $22.49\pm 9.58\%$, $26.77\pm 6.34\%$ and $21.12\pm 6.24\%$ for group I, group II and group III respectively. [Graph III]

- The mean percentage reduction in pericervical dentin thickness on the distal roots post instrumentation was significantly different between the groups in lingual side at $P=0.03$. Multiple comparison between groups revealed that group 3 showed significantly lesser mean percentage reduction in pericervical dentin thickness as compared to group 2 at $P=0.03$. Mean percentage reduction of pericervical dentin thickness in the distal roots for group I was $24.48\pm 6.05\%$, $25.40\pm 7.2\%$ and $22.13\pm 9.67\%$ for group I, group II and group III respectively. [Graph IV]

Discussion

During patient treatment, the clinician needs to consider many factors that will affect the ultimate outcome. These factors can be grouped into 3 categories: the operator needs, the restoration needs, and the tooth needs. The operator needs are the conditions the clinician needs to treat the tooth. The restoration needs are the preparation dimensions and tooth conditions for optimal strength and longevity. The tooth needs are the biologic and structural limitations for a treated tooth to remain predictably functional.^[3] However during treatment, while trying to meet the operator needs and the restoration needs, the tooth needs are often compromised. According to Clark and Khademi (2010) failures of endodontically treated teeth occur not just because of chronic or acute apical lesions only but also because of structural compromise to the teeth that render them useless.^[3]

To assess how the loss of tooth tissue may weaken the tooth, it is important to measure the amount of hard tooth tissue (dentine) removed at each stage of root canal treatment. Though the influence of remaining tooth structure on fracture resistance is evaluated by many researchers,^[4] however, only few studies have quantified the amount of tooth structure removed during these preparations i.e. after completion of biomechanical preparation.

Hence the aim of this study was to determine the effect of biomechanical preparation using three different NiTi file system of fifth generation- Protaper Next, Revo S and One shape on the pericervical dentin thickness in mandibular molars. This study intends to shift the focus into the cervical area of tooth and create for an endorestorative interface.

PCD is the dentin near the alveolar crest. Although the apex of the root can be amputated, and the coronal third

of the clinical crown removed and replaced prosthetically, the dentin near the alveolar crest is nonreplaceable.^[3] This critical zone, roughly 4 mm above the crestal bone and extending 4 mm apical to the crestal bone, is important for 3 reasons: ferrule, fracturing, and dentin tubule orifice proximity from inside to out. The research is unequivocal; long-term retention of the tooth and resistance to fracturing are directly related to the amount of residual tooth structure.

In the present study 30 extracted mandibular molars were used to evaluate pericervical dentin thickness after biomechanical preparation. Mandibular molars were used in this study because they reportedly comprise the most common extracted tooth profile within endodontically treated posterior teeth.^[6]

During the last few decades, a number of methodologies have been described to assess dentin thickness including radiographic comparisons,^[7] series of interlocking trays and laser profilometry,^[8] computed tomography,^[9] ultrasonic micrometer,^[5] serial sectioning of teeth and stereomicroscopy,^[10] digital caliper,^[11] optical coherence tomography,^[12] micro computed tomography,^[13] and multislice computed tomography.^[14] Computed beam tomography was used in the present study to analyse cervical dentin thickness of mandibular molars. This methodology permits observations of the teeth in three-dimensional planes and allows calculations of the amount of removed dentin during biomechanical preparation and tooth preparation without complicated procedures, destructive sectioning of the specimens or loss of the root material during sectioning. In addition, cone beam computed tomography images have an accurate scale, decreasing the potential of a radiographic or photographic transfer error.^[15]

In this study the effect of fifth generation rotary files – Protaper Next, One Shape and Revo S, on the pericervical dentin thickness in mandibular molars was compared. For reproducibility and better comparison, the sample teeth in all the three groups were prepared to an apical diameter #25 and 0.06 taper. PTN files (Dentsply) were used in sequence: Glide path files P1, P2; followed by X1 (17/0.04), X2 (25/0.06). Revo-S (Micro Mega) shaping instruments used in the sequence: SC1(#25/0.06), SC2 (#25/0.04), and SU (#25/0.06). The single file NITI instrument One Shape of size #25/0.06 taper was also used for root canal preparation.

The mean percentage reduction in pericervical dentin thickness was reported to be $23.48\pm 9.77\%$ for group 1, $26.08\pm 9.88\%$ for group 2 and $22.20\pm 6.24\%$ for group 3.

The results were in accordance with the study of Brasil SC et al. (2017) in which it was observed that after preparation with Protaper Next, all the root canals had a

diameter that was not larger than 35% of the root diameter at the coronal and middle third segments.^[13]

Ikram et al. (2009) reported the volume of hard tooth tissue lost after root canal preparation with ProTaper rotary instruments to be 13.7 +/- 6.7%.^[16]

It has been proposed that although the apical canal diameter should be large enough to control infection, coronal enlargement should be performed carefully to avoid weakening the root.^[17]

According to Mowafy et al. (1986), the risk of root fracture is increased when the canal width is larger than 40% of root width.^[18] In this study, in no specimen did the canal width exceed 40% of the root width after biomechanical preparation.

Multiple comparison between groups revealed that group 3 (Revo S) showed significantly lesser mean percentage reduction in dentin thickness as compared to group 2 (Protaper Next) at P=0.03. This was in accordance with the study of Jain D et al. (2015) in which Revo S system (#25,.06 taper) removed less dentin than PTN (#25,.06) and One Shape (#25,.06 taper).

Mesial roots of lower molars are naturally more susceptible to excessive dentin removal and risk of fracture because their mesiodistal diameter is smaller than the buccolingual diameter.^[18] The danger zones or the risk areas are located in the distal walls of the mesial canals and have thin dentin walls interposed between the root canal and the furcation region. The occurrence of perforations and root fractures during endodontic instrumentation occurs more frequently in these areas.^[19] Lim and Stock (1987) has determined an arbitrary value of 0.3 mm as the minimum canal wall thickness that should remain after instrumentation to prevent perforation or vertical root fracture.^[20] In this study, in no specimen did the remaining dentin thickness reduce to less than 0.3mm. However, values as small as 0.6 mm were recorded in the danger zones.

Directed dentin and enamel conservation is the best and only proven method to buttress the endodontically treated molar. No man-made material or technique can compensate for tooth structure lost in key areas of the PCD.^[3] The most current evolution is a minimalistic approach by shifting toward greater dentin preservation and idealizing the endodontic-restorative interface.^[21]

Conclusion

Within the limitations of this study, following conclusions can be made:

- There was significant loss of tooth structure in the pericervical region following root canal instrumentation. Biomechanical preparation resulted in

a loss of 25.72% of pericervical dentin thickness below CEJ.

- Among the three groups, Revo S showed least amount of dentin removal followed by One Shape and Protaper Next.

So, to conclude, our treatment should also aim at well preserved PCD to buttress the tooth without detracting from the Schilder objectives.

“Our objective should be the perpetual preservation of what remains than the meticulous restoration of what is missing”

Dr M.M De Van

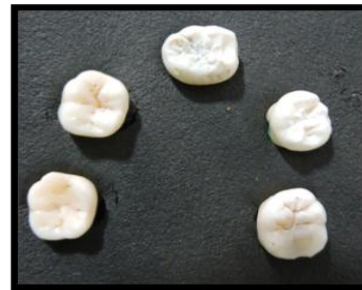

Figure a: Custom made template,

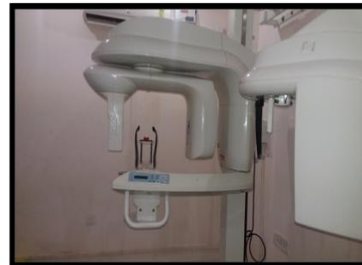

Figure b: The CBCT unit (CS 9000 3D),

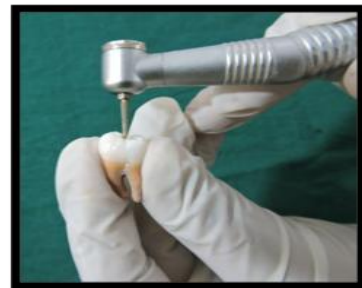

Figure c: Access Cavity Preparation,

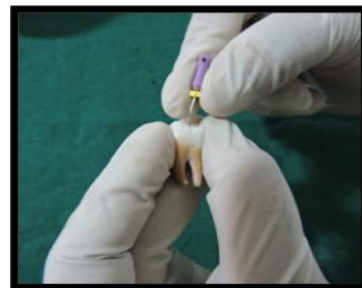

Figure d: Working length determination,

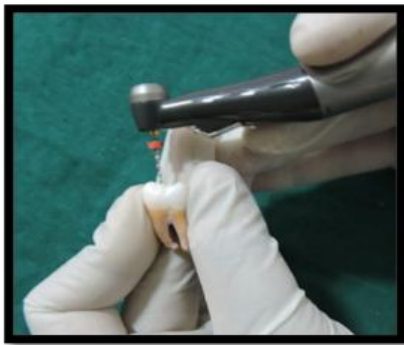

Figure e: Root Canal Preparation,




Figure f: Pre-operative CBCT image,


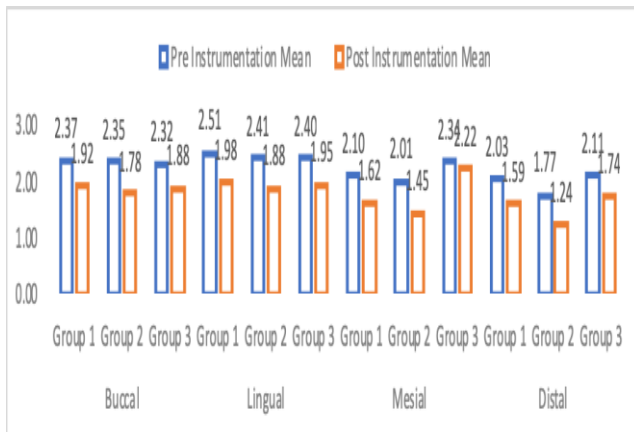
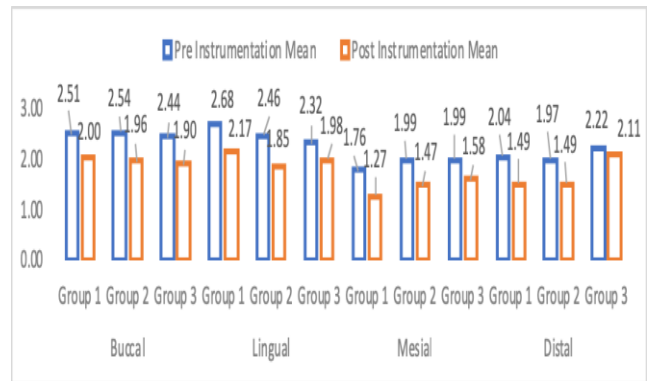


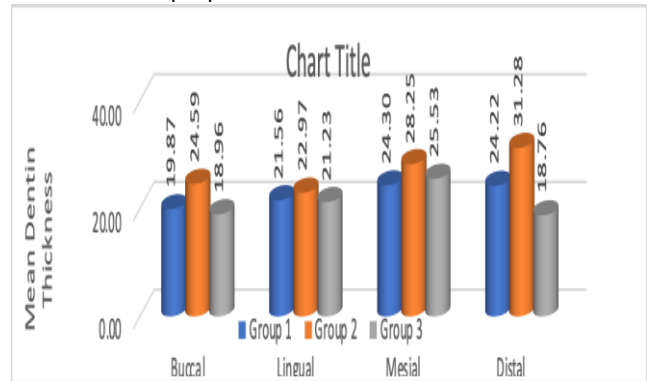
Figure g: Post-operative CBCT image



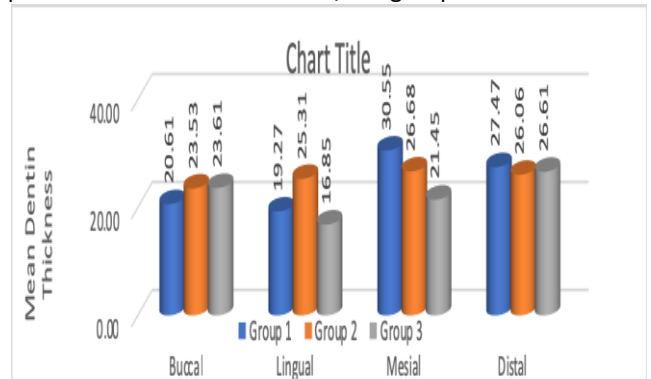
Graph 1: Mean pericervical dentin thickness after biomechanical preparation on mesial roots



Graph 2: Mean pericervical dentin thickness after biomechanical preparation on distal roots



Graph 3: Comparison of mean percentage reduction in pericervical dentin thickness b/w 3 groups on mesial roots



Graph 4: Comparison of mean percentage reduction in pericervical dentin thickness b/w 3 groups on distal roots

References

1. Cohen, Hargreaves KM, Berman LH, Rotstein I (2011) Pathways of the pulp. 11th edition. Mosby-Year Book, St. Louis.
2. Arunpradiktul, Saengsanon S, Pakviwat W. Fracture resistance of endodontically treated teeth: Three walls versus four walls of remaining coronal tooth structure. Int J Prosthodont. 2009; 18:49-53.
3. Clark D, Khademi J. Modern Molar Endodontic Access and Directed Dentin Conservation. Dent Clin Am. 2010; 54:249-273.
4. Al-Wahadini A, Gutteridge DL. An in vitro investigation into the effects of coronal dentine on the strength of a tooth restored with a cemented post and partial core restoration. Int Endod J. 2002; 35:913-8.

5. Hatton HF, Pashley DH, Shunk J and Gregory PS. Invitro and in vivo measurement of remaining dentin thickness. *Int Endod J*.1994; 20:12.
6. Al Amri Md, Al Johani S, Sherfuddin H. Fracture resistance of endodontically treated mandibular first molars with conservative access cavity and different restorative techniques: An in-vitro study. *Aust Endod J* 2016;42(3):124-131.
7. Katz A, Tamse A. A combined radiographic and computerized scanning method to evaluate remaining dentine thickness in mandibular incisors after various intracanal procedures. *Int Endod J*.2003;36.682-686.
8. Bandlish RB, McDonald, Setchell DJ. Assessment of the amount of remaining dentine thickness in root treated teeth. *J Dent*. 2006;34(9):699-708.
9. Nagaraja S and Murthy S. CT evaluation of canal preparation using rotary and hand Ni-Ti instruments: An in vitro study. *J Conserv Dent*. 2010;13(1):16-22.
10. Suaia TS, Gomes PB, Pinheiro TE, Vadrihi L. Thickness of dentin in mesial roots of mandibular molars with different lengths. *Int Endod J*. 2010;43,555-559.
11. Alomari KD, Barrieshi KM, Al- Awadhi SA. Effect of post length and diameter on remaining dentin thickness in maxillary central and lateral incisors. *Int Endod J*. 2011; 44:956-966.
12. Majkut P, Sadr A, Shimada Y, Sumi Y, Tagami J. Validation of Optical Coherence Tomography against Micro-computed Tomography for Evaluation of Remaining Coronal Dentin Thickness. *J Endod*. 2015;41(8):1349-52.
13. Brasil SC, Marcelianoalves MF, Marques ML et al Canal transportation, unprepared areas and dentin removal after preparation with BT Race and Protaper Next systems. *J endod* 2017;43(10):1683-1687.
14. Mahran AH and AboEl-Fotouh. Comparison of effects of Protaper, Heroshaper, and Gates Glidden Burs on cervical Dentin Thickness and Root Canal Volume by using Multislice Computed Tomography. *J Endod*. 2008; 34:1219-1222.
15. Scarfe Wc, Farman AG. What is cone beam CT and how does it work? *Dent Clin North Am* 2008; 52:707-30.
16. Ikram OH, Patel S, Sauro S, Mannocei F. Micro-computed tomography of tooth tissue volume changes following endodontic procedures and post space preparation. *Int Endod J*. 2009;42(12):1071-6.
17. Wilcox LR, Roskelley C, Sutton T. The relationship of root canal enlargement to vertical root fracture. *J Endod* 1997; 23:533-4.
18. El Mowafy OM, Watts DC. Fracture toughness of human dentin. *J Dent Res*. 1986; 65:677-681.
19. Sheila Silva Leita Pinto and Helio Pereira Lopes. The internal anatomy of danger zones of mandibular molars: A cone beam computed tomography study. *J Conserv Dent*. 2018;21(5):481-484.
20. Lim SS, Stock CJR. The risk of perforation in the curved canal: anticurvature filing compared with the stepback technique. *Int Endod J*.1987; 20:33-9.
21. Martin Trope. Bio-minimalism: Trends and transitions in endodontics. *J Dent*. 2016;13:231-5.