



EFFICACY OF FRACTIONAL CO₂ LASER WITH TOPICAL PLATELET RICH PLASMA IN TREATMENT OF ACNE SCARS

Dr. Kiran Puram¹, Dr. Rachana Lau², Dr. Anand Asia³

¹Post Graduate Student, Department of Dermatology, Venereology and Leprosy, Government Medical College, Akola, Maharashtra

²Associate Professor, Department of Dermatology, Venereology and Leprosy, Government Medical College, Akola, Maharashtra

³Professor, Department of Dermatology, Venereology and Leprosy, Government Medical College, Akola, Maharashtra

Conflicts of Interest: Nil

Corresponding author: Dr. Kiran Puram

DOI: <https://doi.org/10.32553/ijmsdr.v4i11.706>

Abstract:

Background: Acne scars are most distressing sequelae of acne vulgaris having a major impact on psychosocial aspect and quality of life of an individual. In spite of various therapeutic modalities available treatment of acne scars is challenging. Resurfacing techniques such as Fractional CO₂ Laser is a well-established treatment option for acne scar. Platelet-Rich Plasma (PRP), an autologous preparation of growth factors helps in wound healing and tissue regeneration.

Aim: To study the efficacy of Fractional CO₂ Laser with Topical Platelet-Rich Plasma in Acne scars.

Materials and Methods: A total of 15 patients with atrophic facial acne scar, aged 18-40 years attending Outpatient Department of Dermatology, Venereology and Leprosy at tertiary care centre during January 2019 to December 2019 were included for this interventional study after written informed consent. The patients underwent six sessions of Fractional CO₂ Laser with Topical application of Platelet-Rich Plasma at monthly intervals. Pre and post treatment comparative Goodman and Baron's quantitative global scarring grading and patients self-assessment score were used for assessment.

Results: At the end of study mild reduction in Goodman and Baron's quantitative score for acne scar was noted in 13 patients (86.6%). Mean Goodman and Baron's quantitative score at 4 weeks after sixth sitting was 13.13 ± 4.60. On patients self-assessment moderate resolution of acne scar was noted in 8 patients (53.3%).

Conclusion: Fractional CO₂ Laser with Topical Platelet-Rich Plasma application has mild to moderate improvement of acne scars and shorter down time of Fractional CO₂ Laser.

Keywords: Acne scar, Fractional Co₂ Laser, Topical Platelet-Rich Plasma

Introduction:

The prevalence of acne scarring is estimated to be between 1% and 11% in the general population, with scarring affecting the face in most of the cases.^[1,2] Acne scars are result of compromised collagen production during the natural wound healing process, causing topographical depressions.^[3] Depending on whether there is a loss or accumulation of collagen, there are two types of acne scars as, atrophic and hypertrophic.^[4] Atrophic scars can be classified into icepick, rolling and boxcar scars.^[5] Acne scar have a major impact on the psychosocial aspect of an individual due to the assumption of importance of facial appearance in overall personality, social interaction and job opportunities, thereby affecting the quality of life. Various therapeutic modalities in treatment of acne scars includes chemical peels, methods of tissue augmentation, dermabrasion, radiofrequency, ablative and non-ablative lasers and surgical techniques such as subcision, punch graft and punch excision. Facial resurfacing with fractional lasers is currently claimed to be one of the most effective treatment options for facial scars.^[6,7] Ablative fractional

carbon dioxide lasers generate thermal energy targeting the separated columns of skin at specific depths called the microthermal treatment zones.^[8,9] In addition, the enormous heat generated during ablative fractional carbon dioxide laser treatment can remove dermal tissue and bring about tissue shrinkage in the adjacent dermal collagen accompanied by collagen remodeling and skin tightening.^[10] Platelet-rich plasma (PRP) therapy is an autologous preparation of platelets in concentrated plasma. PRP contains significant amounts of platelet-derived growth factor, transforming growth factor, vascular endothelial growth factor, epidermal growth factor and fibroblast growth factor. This properties of PRP attributes to its role in wound healing, tissue repair and remodeling. Intradermal PRP is frequently done for improvement of acne scars. However, pain due to repeated injection, edema and redness are common with intradermal PRP. Studies regarding topical use of PRP with fractional CO₂ laser for acne scars are sparse. Combination of therapeutic modalities in treatment of acne scars sequentially or rotationally may help to improve outcome and minimize side-effects. With this background an

interventional study was undertaken to assess the efficacy of fractional CO₂ laser with topical platelet rich plasma in treatment of acne scars.

Materials and Methods:

Fifteen patients with atrophic facial acne scar of age group 18-40 years attending Outpatient Department of Dermatology, Venereology and Leprosy at tertiary care centre during January 2019 to December 2019 were enrolled in this study after approval of the Institutional Ethical committee and written informed consent. Those with a history of herpes simplex infection, any active inflammation, keloid formation, diabetes mellitus, collagen vascular disease, oral isotretinoin use within the previous 6 months, ablative or non-ablative laser skin resurfacing in the previous 12 months, photosensitivity, bleeding diathesis, pregnancy, lactation and patients with unrealistic high expectations were excluded. Demographic profile, history, clinical examination and baseline investigations were done. Goodman and Baron's quantitative global scarring grading system was used for acne scar grading of patients. Topical anaesthetic (prilocaine 2.5% + lidocaine 2.5%) cream was applied for 30–45 min before the procedure in each sitting. After gentle cleaning of topical anaesthetic cream, 30 mJ (30%) energy was delivered in the first session with 10% increase in every subsequent session till maximum tolerable limit of energy and then successive sessions with same dose were given. Fractional CO₂ laser session was immediately followed by topical application of PRP and the site of PRP application was allowed to dry. Patients received total six such sittings at monthly interval. Clinical photographs were taken before and after each session. Post session undesired or adverse effects, if any were recorded. Patients were instructed to use a physical sunscreen twice during daytime and were counselled for the post session development of transient erythema, edema and dryness and to immediately report undesired events, if any. Post session follow up done on third day for erythema, edema and crusting at treated areas.

Method of Platelet-Rich Plasma preparation:

Platelet-Rich Plasma was prepared by double spin method. Whole blood sample was obtained from patient's medial cubital vein under aseptic conditions and transferred to a tube containing an anticoagulant and centrifuged at 2000 rpm for 10 min. Platelet-poor plasma, PRP, and a few RBCs thus obtained were aspirated into a new tube and centrifuged at 4000 rpm for 20 min. The middle layer consisting of the PRP was aspirated for topical application immediately after the Fractional CO₂ laser session.

Assessment was done 4 weeks after last session (at 7th month) by comparing Goodman and Baron's quantitative global scarring grading for acne scar before and after

treatment and self-assessment of acne scars by the patient after the treatment. Data was pooled in Microsoft excel 2019 and analyzed statistically.

Results and Discussion:

Out of fifteen patients of atrophic acne scars 11 were male and 4 were females.(Figure 1) Mean age of patient was 23.4 ± 4.02 years. The mean duration of acne scars was 3.06 ± 1.77 years. One patient was married and 14 were unmarried. Thirteen patients (86.6%) had rolling scars. The mean baseline Goodman and Baron's quantitative score was 16.13 ± 4.52 and mean final Goodman and Baron's quantitative score was 13.13 ± 4.60 .(Figure 2) Mild reduction in Goodman and Baron's quantitative score was noted in 13 (86.6%) patients while 2 (13.3%) patients had moderate reduction in Goodman and Baron's quantitative score after the final session.(Table 1) (Figures 3-6) On patient self-assessment of scars after 4 weeks of final session mild resolution was noted by 6 (40%) patients, moderate resolution by 8 (53.3%) patients and good resolution by 1(6.6%) patient.(Figure 7) No undesired or any adverse effects were noted.

In our study at 4 weeks after the final session mild to moderate reduction in Goodman and Baron's quantitative score was noted. Zhu et al in their study used erbium fractional laser with topical PRP in 22 patients with acne scar and reported excellent clinical improvement and patient satisfaction on the PRP-treated patients.^[11] In a split face comparison study of 30 patients Kar et al noted statistically significant improvement in the quantitative scoring of scars on both Fractional CO₂ laser -only treated side (8.66 ± 5.37) and Fractional CO₂ laser with topical PRP treated side (7.33 ± 5.68). But the difference between Fractional CO₂ laser -only and Fractional CO₂ laser with topical PRP was not statistically significant at the end of their study.^[12] In our study moderate resolution of acne scar was noted by patients on self-assessment which indicates that patients were satisfied with the treatment outcome. Several studies have also observed satisfactory outcome of treatment by the patients.^[13,14,15] In our study patients were followed up on the third day after the procedure for subjective assessment of symptoms such as redness, swelling and crusting in the treated areas and observed that each of these symptoms were milder and had a shorter down-time. Gawdat et al used topical and intradermal platelet-rich plasma after ablative fractional carbon dioxide laser for acne scar treatment in 30 patients. In their study they reported in addition to synergistic effects on clinical response and patient satisfaction after adding platelet-rich plasma to Fractional CO₂ laser, they also noted that side effects were fewer on the platelet-rich plasma sides (both intradermal and topical) than the other sides.^[16] Studies conducted by Nita et al and Nofal et al also reported less erythema after adding platelet-rich

plasma to laser therapy.^[17,18] However, Faghihi et al noted that though there was better scar correction on the Fractional CO₂ laser with intradermal PRP side, it was not statistically significant and that there were more local side effects on the PRP-treated side.^[14] In our study Platelet Rich Plasma was applied topically over the areas of post Fractional CO₂ laser session thereby reducing the component of pain and trauma due to repeated injection of PRP on the laser damaged area.

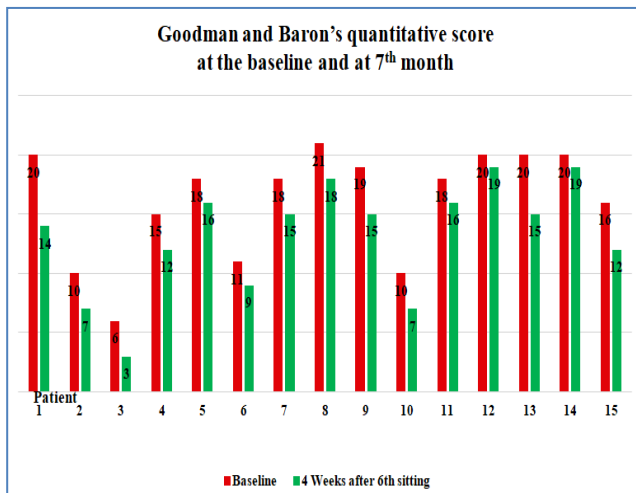
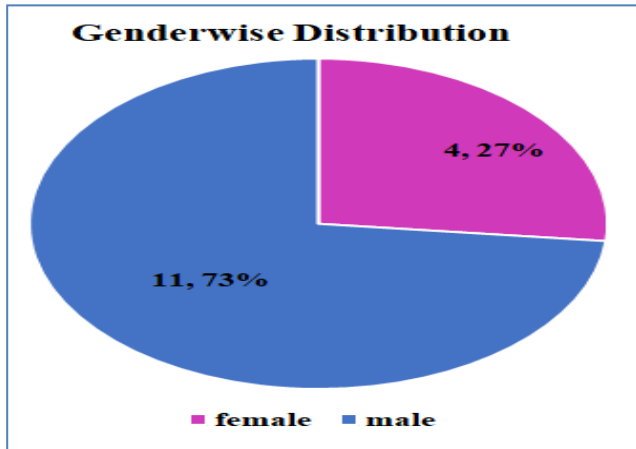


Table 1: showing status of improvement as per Goodman and Baron's quantitative score

Serial No.	Improvement Status	No. of Patients
1.	Mild reduction in Goodman and Baron's quantitative score	13 (86.6%)
2.	Moderate reduction in Goodman and Baron's quantitative score	02 (13.3%)
3.	Good reduction in Goodman and Baron's quantitative score	0
4.	Very good reduction in Goodman and Baron's quantitative score	0

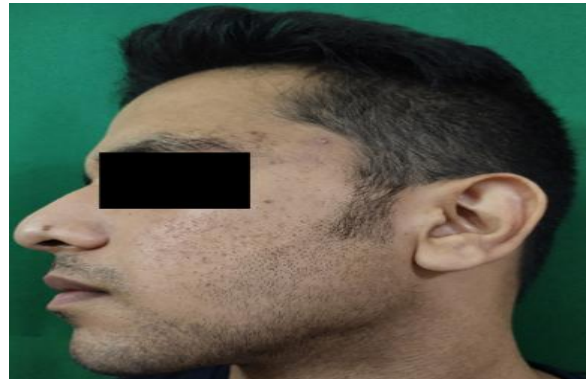
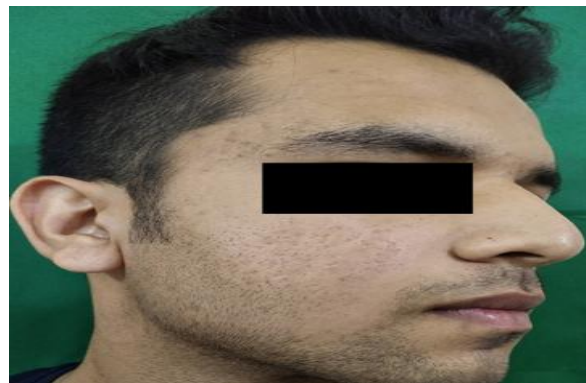
Figure 3 and 4: Baseline clinical photograph showing acne scars

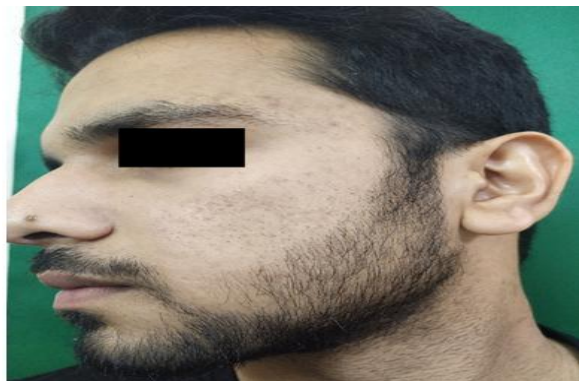
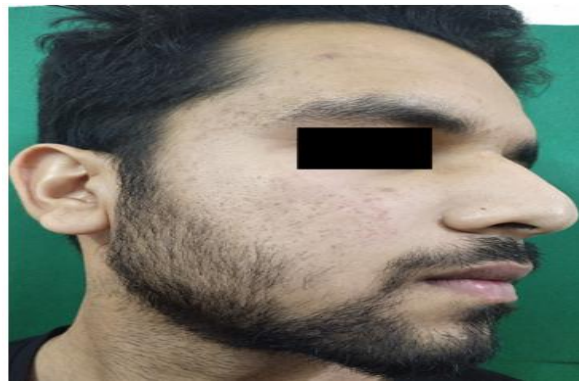
Figure 5 and 6: Clinical photograph at 7th month of treatment

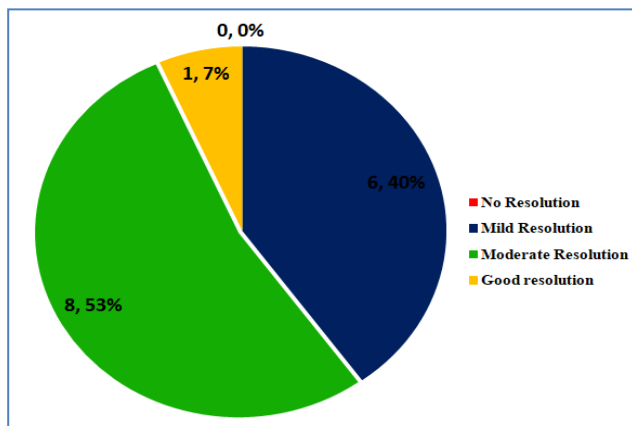


Figure 7: Patients Self Assessment Of Acne Scars After Treatment

Conclusion:

Combination of repeated injections of PRP along with Fractional CO₂ laser has shown good results in treatment of acne scars. Application of topical PRP along with Fractional CO₂ laser may prove to be a good adjunct modality to injectable PRP as seen in our study. Topical application of PRP avoids pain due to repeated injection of intradermal PRP and improves the down-time of Fractional CO₂ laser. As scars modulate over a long period of time more number of sessions and long term follow up may be necessary for better assessment of resolution of acne scars. However, more studies with larger sample size and randomized controlled trials are required to put more light on synergistic role of Fractional CO₂ laser with topical Platelet Rich Plasma in outcome of acne scars.

References:

1. Fife D. Evaluation of Acne Scars: How to Assess Them and What to Tell the Patient. *Dermatol Clin*. 2016;34(2):207-213.
2. Connolly D, Vu HL, Mariwalla K, Saedi N. Acne Scarring-Pathogenesis, Evaluation, and Treatment Options. *J Clin Aesthet Dermatol*. 2017;10(9):12-23
3. Zaenglein AL and Thiboutot DM. *Dermatology*. In: Bologna JL, Jorizzo JL and Rapini R (Eds). *Acne Vulgaris*. Mosby Publishing; 2008. 213-4.
4. Petrov A, Pljakovska V. Fractional Carbon Dioxide Laser in Treatment of Acne Scars. *Open Access Maced J Med Sci*. 2016 Mar 15; 4(1):38-42. <http://dx.doi.org/10.3889/oamjms.2016.004>
5. Jacob CI, Dover JS, Kaminer MS. Acne scarring: a classification system and review of treatment options. *J Am Acad Dermatol*. 2001;45:109-17
6. Geronemus RG. Fractional photothermolysis: Current and future applications. *Lasers Surg Med* 2006; 38: 169-76.
7. Rivera AE. Acne scarring: A review and current treatment modalities. *J Am Acad Dermatol* 2008;59:659-76.
8. Manstein D, Herron GS, Sink RK, Tanner H, Anderson RR. Fractional photothermolysis: A new concept for cutaneous remodeling using microscopic patterns of thermal injury. *Lasers Surg Med* 2004;34:426-38.
9. Alexiades-Armenakas MR, Dover JS, Arndt KA. The spectrum of laser skin resurfacing: Nonablative, fractional, and ablative laser resurfacing. *J Am Acad Dermatol* 2008;58:719-37.
10. Hantash BM, Bedi VP, Chan KF, Zachary CB. *Ex vivo* histological characterization of a novel ablative fractional resurfacing device. *Lasers Surg Med* 2007;39:87-95.
11. Zhu JT, Xuan M, Zhang YN, Liu HW, Cai JH, Wu YH, et al. The efficacy of autologous platelet-rich plasma combined with erbium fractional laser therapy for facial acne scars or acne. *Mol Med Rep* 2013;8:233-7.
12. Kar BR, Raj C. Fractional CO₂ laser vs fractional CO₂ with topical platelet-rich plasma in the treatment of acne scars: A split-face comparison trial. *J Cutan Aesthet Surg* 2018;10:136-44.
13. Shin MK, Lee JH, Lee SJ, Kim NI. Platelet-rich plasma combined with fractional laser therapy for skin rejuvenation. *Dermatol Surg* 2012;38:623-30.
14. Faghihi G, Keyvan S, Asilian A, Nouraei S, Behfar S, Nilforoushadeh MA. Efficacy of autologous platelet-rich plasma combined with fractional ablative carbon dioxide resurfacing laser in treatment of facial atrophic acne scars: a split-face randomized clinical trial. *Indian J Dermatol Venereol Leprol* 2016;82:162-8.
15. Shah S, Mehta B, Borkar M, Aswani R. Study of safety and efficacy of autologous platelet rich plasma combined with fractional CO₂ laser in the treatment of post acne scars: a comparative simultaneous split-face study. *Int J Res Med Sci* 2017;5:1344-51.
16. Gawdat HI, Hegazy RA, Fawzy MM, Fathy M. Autologous platelet rich plasma: Topical versus intradermal after fractional ablative carbon dioxide laser treatment of atrophic acne scars. *Dermatol Surg* 2014;40:152-61.
17. Nita AC, Orzan OA, Filipescu M, Jianu D. Fat graft, laser CO₂ and platelet-rich-plasma synergy in scars treatment. *J Med Life* 2013;6:430-3.
18. Nofal E, Helmy A, Nofal A, Alakad R, Nasr M. Platelet-rich plasma versus CROSS technique with 100% trichloroacetic acid versus combined skin needling and platelet rich plasma in the treatment of atrophic acne scars: A comparative study. *Dermatol Surg* 2014;40:864-73.