



# Neurological Manifestations in Vitamin B12 Deficient Children: A Prospective Observational Study

Bhartendu Dave, Sonam Sharma\*

<sup>1</sup>MD (Pediatrics), Medical Officer, Maternal and Child Health Care Umaid Hospitals, Jodhpur, Rajasthan

<sup>2</sup>MD (Pediatrics), Senior Resident, Ananta Hospital, Udaipur.

Conflicts of Interest: Nil

Corresponding author: Sonam Sharma

DOI: <https://doi.org/10.32553/ijmsdr.v6i8.944>

## Abstract

**Background and aim:** Neurological manifestations in vitamin B12 deficient children in common. The present study determined neurological manifestations in vitamin B12 deficient children in a tertiary care centre in Rajasthan.

**Methods:** This hospital based observational analytical study was conducted in Department of Pediatrics, Dr. S. N. Medical College, Jodhpur after approval of Institutional Ethics Committee (IEC). The study population included Vitamin B12 deficient (<250 picogram/dl) children during September 2019 to August 2020. All children aged 6 months to 5 years admitted in pediatric ward with anaemia (Hb< 11 gm/dl according to WHO Criteria) were screened for serum vitamin B12 levels out of which children having serum vitamin B12 level <250Pg/dl were included in the study.

**Results:** More than half (63.8%) of the children aged between 6 months and 15 months. Male to female ratio was 1.58:1. 78.7% were rural and 60% were from lower socioeconomic class. 85% of the children' family had vegetarian dietary habits. The most common clinical feature was hyperpigmentation of knuckles and skin (85% each) followed by depigmented and sparse hair (70%), and chubby face (42.5%). 65% of the children were found to have neurological manifestations. The most common neurological manifestation was developmental delay (60%) followed by hypotonia (38.7%), exaggerated reflexes (31.2%), and abnormal movements (20%).  
**Conclusion:** There is an urgent demand for early evaluation of the children so prevent further prevent developmental growth of the children.

**Keywords:** Neurological manifestations, vitamin B12, developmental delay

## Introduction

Vitamin B12 deficiency is a condition that is readily amenable to treatment, but its protean manifestations make diagnosis difficult in certain circumstances. Early recognition is essential to reversing the haematological and neurologic dysfunction characteristic of this disorder by means of vitamin supplementation.<sup>1</sup> Varied neurological

manifestations of vitamin B12 deficiency have been known for over 150 years.

Although infants who are deficient in vitamin B12 due to maternal and infant vegetarianism may also be deficient in other nutrients derived from animal-source foods, such as iron and zinc, it is unlikely that the developmental problems associated with vitamin B12

deficiency could be explained by iron or zinc deficiency.

There are at least two possible mechanisms linking vitamin B12 deficiency and abnormal behavior and development: 1) threats to early brain development, possibly through demyelination; and 2) inflammation, possibly simulating an autoimmune process that blocks intrinsic factor for cobalamin absorption, similar to pernicious anemia, an autoimmune disease that blocks intrinsic factor.

Nutrient deficiencies can interfere with early brain development and function, often by restricting the myelination, dendritic arborisation, and synaptic connectivity that occur early in life.<sup>2</sup> The tissue levels of neurotransmitters (e.g., serotonin, dopamine, norepinephrine and acetylcholine) may be altered, resulting in neuroanatomical, neurochemical, or neurometabolic changes. The functional consequences of these alterations vary, depending on the specific nutritional deficiency and the timing of the deficiency relative to the developing neurological processes.

The present study evaluated the neurological manifestations in vitamin B12 deficient children.

### Material and methods

This hospital based observational analytical study was conducted in Department of Pediatrics, Dr. S. N. Medical College, Jodhpur after approval of Institutional Ethics Committee (IEC). The study population included Vitamin B12 deficient (<250 picogram/dl) children aged between 6 months and 5 years during September 2019 to August 2020.

All children aged 6 months to 5 years admitted in pediatric ward with anaemia (Hb< 11 gm/dl according to WHO Criteria) were screened for serum vitamin B12 levels out of which children having serum vitamin B12 level <250Pg/dl (as per lower limit defined by Institute of Medicine

Standing Committee, USA) were included in the study.

Children with an Acute encephalopathy syndrome as per standard epidemiologic case definition, stroke, demyelinating illness, known patient of epilepsy, pre-existing development delay, congenital CNS malformations, any known malignancy, other primary CNS disorders (both acquired and hereditary), children on vitamin B12 supplements (therapeutic or prophylactic) for at least 7 days in last one month, and/or refusal for participation in the study by parents/guardian, were excluded.

### Methodology

All children aged between 6 months and 5 years admitted in a pre-decided Paediatric unit were screened for Hb levels by Complete Blood Counts (CBC). Total 1552 children were hospitalised during this study period out of which 853 children (54.37%) were between the age group of 6 months to 5 years. 361 children diagnosed out of these 853 had anaemia as per WHO criteria (Hb <11 gm/dl). In all these 361 children serum vitamin B12 levels were performed.

For this two ml of serum was collected to estimate serum vitamin B12 levels. Vitamin B12 levels were performed by a competitive chemiluminescent immunoassay.

80 patients out of these 361 had serum vitamin B12 level < 250 pg/dl (as per lower limit defined by Institute of Medicine Standing Committee, USA) and were enrolled after applying exclusion criteria. A detailed history regarding name, age, sex, address, contact number, chief complaints with duration were recorded. Complete birth history, feeding history, dietary history along with antenatal history were recorded. The socioeconomic status of the patients was established based on the Modified Kuppaswamy scale. Complete examination including general and systemic examination and anthropometry was

performed. All the data were then entered into a predesigned proforma for this study. Developmental assessment of these children was performed using Denver II Development Screening Test. Laboratory investigation included complete hemogram, peripheral blood smear and serum vitamin B12 levels.

Data were presented as frequency and percentages.

## Results

### General characteristics

Table 1 shows general characteristics of the study participants. Median age at presentation was 11 months. More than half (63.8%) of the children aged between 6 months and 15 months. Male to female ratio was 1.58:1. 78.7% were rural and 60% were from lower socioeconomic class. 85% of the children' family had vegetarian dietary habits.

**Table 1: General characteristics**

	Frequency	Percentage
<b>Age (In months)</b>		
6-15	51	63.8
15-30	19	23.8
>30	10	12.4
<b>Gender</b>		
Male	49	61.3
Female	31	38.7
<b>Locality</b>		
Rural	63	78.7
Urban	17	21.3
<b>Socio-economic status</b>		
Lower	48	60.0
Middle	28	35.0
Upper	4	5.0
<b>Dietary habits</b>		
Vegetarian	68	85.0
Non- Vegetarian	12	15.0

### Weight for age

Approximately 59% children' weight for age <-3 SD while only one child had weight for age >-1 SD (Table 2).

**Table 2: Severity of Vitamin B12 deficiency**

Weight for age	Frequency	Percentage
<-3SD	47	58.8
-3SD to -2 SD	17	21.2
- 2SD to - 1 SD	15	18.8
>-1SD	1	1.2

### Clinical features

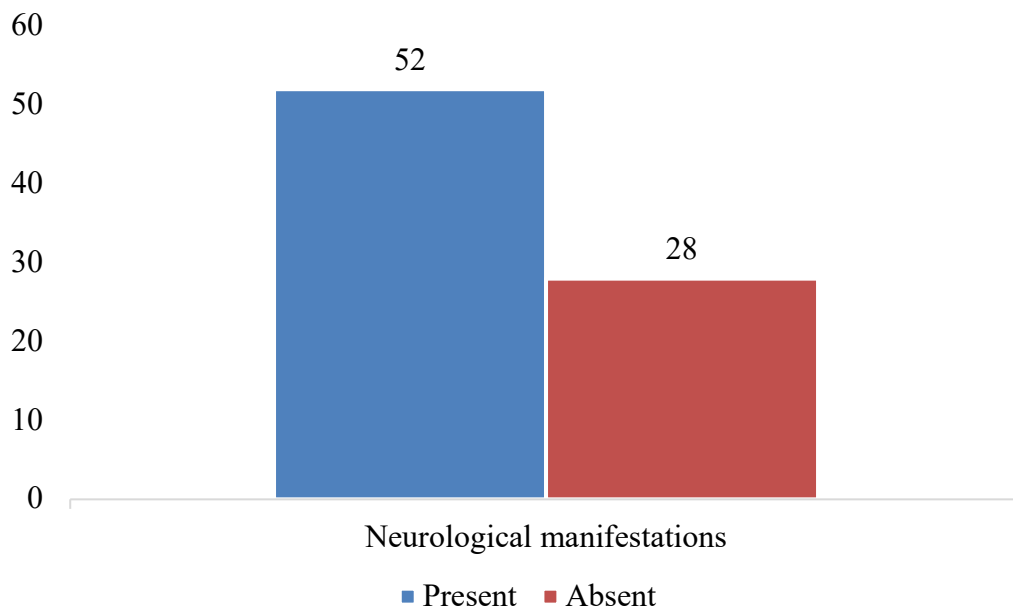
The most common clinical feature was hyperpigmentation of knuckles and skin (85% each) followed by depigmented and sparse hair (70%), and chubby face (42.5%) (Table 3).

**Table 3: Clinical features at presentation in different categories of severity of serum vitamin B12**

Clinical features	Frequency	Percentage
Chubby face	34	42.5
Mouth angular stomatitis	21	26.2
Tongue glossitis	23	28.7
Skin Hyperpigmented	68	85.0
Knuckle hyperpigmentation	68	85.0
Hair depigmented	7	8.7
Hair sparse	9	11.2
Hair sparse & depigmented	56	70.0

### Neurological manifestation

In our study, 65% of the children were found to have neurological manifestations (Figure 1)



**Figure 1: Absence or presence of Neurologic manifestations on presentation**

### Type of neurological manifestations

The most common neurological manifestation was developmental delay (60%) followed by hypotonia (38.7%), exaggerated reflexes (31.2%), and abnormal movements (20%) (Table 4).

**Table 4: Neurological manifestations on presentation**

Neurological manifestations	Frequency	Percentage
Development regression	9	11.2
Seizures	8	10.0
Development delay	48	60.0
<b>Abnormal movement</b>	16	20.0
<b>If yes type of abnormal movement</b>		
Myoclonus	3	3.7
Orofacial lingual movements	3	3.7
High amplitude tremors	10	12.5
<b>Hypotonia</b>	31	38.7
<b>Reflexes</b>		
Depressed	13	16.2
Exaggerated	25	31.2

## Discussion

The present study determined the neurological manifestations in vitamin B12 deficient children. In our study, there was male preponderance. There is a bias amongst families in rural India to seek more attention for male children reflecting in higher number of male children getting access to health care. In other studies, by Mittal *et al*<sup>3</sup> and Azad *et al*<sup>4</sup>, higher proportion of male children (68% male and 32% female; 71% male and 29% female) were reported.

In our study, median age of presentation was 11 months which is similar to median age of 11 months observed in another study by Jain *et al* (2015) from India.<sup>5</sup> In the Turkish study median age at presentation was observed as 13 months while in another Indian study by Goraya *et al*<sup>6</sup>, the mean age was observed to be 13.7 months. Although, there is not clear reason for this mean age of presentation; however, it is possible that predominant breast feeding coupled with delayed introduction of complementary feeding may deplete vitamin B12 stores which may last only for around 3-4 months if the diet is inadequate in vitamin B12.

Most of the hospitalised patients in India and specifically in Western Rajasthan are from a rural background and it came as no surprise that in the current study 78.25% of the total

studied population was from rural background while 21.25% were from urban background. One of the important reasons for high frequency of vitamin B12 deficiency in rural region may be due to inadequate consumption of animal products due to poverty.

In our study, maximum cases (60.00%) were from lower socioeconomic class followed by middle class (35.00%) and only a minority from upper class (5.00%). Children from lower socioeconomic status had significantly lower levels of vitamin B12 in comparison to middle and upper class in mild to moderate group ( $p < 0.001$ ). Mittal *et al*<sup>3</sup> in their study reported that 52.3% of upper or middle and 60.3% lower class infants were deficient in vitamin B12; however, the relation was insignificant ( $p = 0.42$ ).

85% of the children in the current study were vegetarian and 15% were non-vegetarian. In the study by Mittal *et al*<sup>3</sup>, prevalence of vitamin B 12 deficiency was 68.90% in vegetarian mothers and 52% in non-vegetarian mothers of enrolled vitamin B12 deficient infants between 1-6 months. Higher rates of deficiency were reported among vegans compared with vegetarians and among individuals who had adhered to a vegetarian diet since birth compared with those who had adopted such a diet later in life.

In our study, apart from pallor (seen in 100% patients), the most common clinical findings were hyper-pigmented skin (85%), pigmentation of distal extremities (85%), sparse and de-pigmented hair (70%) and angular chelosis/glossitis (21.8%). These findings were more common in those with severe deficiency compared to those with mild to moderate deficiency. Previous studies have reported these clinical features in a varying percentage of patients. Goraya et al<sup>6</sup> reported skin hyperpigmentation and sparse and depigmented hair in all 27 patients (100%). Jain et al reported knuckle hyperpigmentation in 5 (35%) cases out of 14 patients.<sup>5</sup>

### Conclusion

Neurological manifestations are indeed the most common and important clinical presentation of vitamin B12 deficiency syndrome. There is an urgent need to focus on evaluation of vitamin B12 as a routine test in early childhood.

### References

1. Shariieff AZ, Raffel J, Zee DS. Vitamin B12 deficiency with bilateral globus pallidus abnormalities. *Arch Neurol.* 2012;69:769–72
2. Lovblad K, Ramelli G, Remonda L, Nirkko AC, Ozdoba C, Schroth G. Retardation of myelination due to dietary vitamin B12 deficiency: Cranial MRI findings. *Pediatr Radiol.* 1007;27:155–158
3. Mittal M, Bansal V, Jain R, Dabla PK. Perturbing Status of Vitamin B12 in Indian Infants and Their Mothers. *Food Nutr Bull.* 2017 Jun;38(2):209-215
4. Azad C, Jat KR, Kaur J, Guglani V, Palta A, Tiwari A, Bansal D. Vitamin B12 status and neurodevelopmental delay in Indian infants: a hospital-based cross-sectional study. *Paediatr Int Child Health.* 2020 May;40(2):78-84
5. Jain, R, Singh, A, Mittal, M, Talukdar, B. Vitamin B12 deficiency in children a treatable cause of neurodevelopmental delay. *J Child Neurol.* 2015;30(5):641–643
6. Goraya JS, Kaur S. Infantile tremor syndrome: A review and critical appraisal of its etiology. *J Pediatr Neurosci.* 2016;11(4):298-304